



Simulation and education

Bystander cricothyroidotomy with household devices – A fresh cadaveric feasibility study[☆]Christian Braun^a, Ulrich Kisser^b, Astrid Huber^b, Klaus Stelter^{c,*}^a Institute of Legal Medicine and Forensic Sciences, Ludwig-Maximilians-Universität, Munich, Germany^b Department of Head and Neck Surgery, Ludwig-Maximilians-Universität, Munich, Germany^c HNO Zentrum Mangfall-Inn, Rosenheim, Germany

ARTICLE INFO

Article history:

Received 19 July 2016

Received in revised form

18 September 2016

Accepted 9 October 2016

Keywords:

Cricothyroidotomy

Pocket knife

Ballpoint pen

Household

Bystander

Fresh cadavers

ABSTRACT

Introduction: In various motion pictures, medical TV shows and internet chatrooms, non-medical devices were presented as tools for life-saving cricothyroidotomies. However, there is uncertainty about whether it is possible for a bystander to perform a cricothyroidotomy and maintain gas exchange using improvised household items. This study examines the ability of bystanders to carry out an emergency cricothyroidotomy in fresh human cadavers using only a pocket knife and a ballpoint pen.

Materials and methods: Two commonly available pens and five different pocket knives were used. Ten participants with no or only basic anatomical knowledge had to choose one of the pens and one of the knives and were asked to perform a cricothyroidotomy as quickly as possible after a short introduction. Primary successful outcome was a correct placement of the pen barrel and was determined by the thoracic lifting in a mouth-to-pen resuscitation.

Results: Eight (80%) participants performed a successful approach to the upper airway with a thoracic lifting at the end. Five participants performed a cricothyroidotomy and three performed an unintentional tracheotomy. Injuries to muscles and cartilage were common, but no major vascular damage was seen in the post-procedural autopsy. However, mean time in the successful group was 243 s.

Conclusion: In this cadaveric model, bystanders with variable medical knowledge were able to establish an emergency cricothyroidotomy in 80% of the cases only using a pocketknife and a ballpoint pen. No major complications (particularly injuries of arterial blood vessels or the oesophagus) occurred. Although a pocket knife and ballpoint pen cricothyroidotomy seem a very extreme procedure for a bystander, the results of our study suggest that it is a feasible option in an extreme scenario. For a better outcome, the anatomical landmarks of the neck and the incision techniques should be taught in emergency courses.

© 2016 Elsevier Ireland Ltd. All rights reserved.

Introduction

Acute airway obstruction is a rare but potentially life-threatening situation. If neither an intubation nor a mask or mouth-to-mouth ventilation is possible a cricothyroidotomy may be necessary. Paix et al. describe 24 prehospital cases where a cricothyroidotomy was performed as a primary procedure either because of anatomical injury or lack of access to the airway in an entrapped patient.¹ Even in a pre-hospital arena, cricothyroidotomy requires equipment and a certain medical expertise.

There exist commercially available cricothyroidotomy sets (i.e. Quicktrach[®]) with included tracheostomy cannulas and sharp incision trocars. But, in the prehospital setting, the medical equipment required to perform this procedure may not be readily available to bystanders and nonmedical objects may need to be adapted in order to perform this procedure. There is a paucity of literature examining surgical cricothyroidotomy in the emergency setting^{2,3} and only one case report describes the use of improvised non-medical equipment.⁴

In various motion pictures (i.e. “SAW V”, the german “Tatort”), medical TV shows (“Dr. House: Twenty Vicodin, Season 8, film 1”) and internet chatrooms, ballpoint pens and knives were presented as tools for a life-saving cricothyroidotomy. Even some medical and survival training books recommend a knife for the incision and the barrel of a ballpoint pen as a cannula.^{5–7}

Platt-Mills et al. report in their cadaveric study in fresh cadavers a method of improvised cricothyroidotomy using the spike of a

[☆] A Spanish translated version of the summary of this article appears as Appendix in the final online version at <http://dx.doi.org/10.1016/j.resuscitation.2016.10.015>.

* Corresponding author. Klaus Stelter, MD, HNO Zentrum Mangfall-Inn, Muenchener Str. 27, 83022 Rosenheim, Germany.

E-mail address: Klaus.stelter@med.uni-muenchen.de (K. Stelter).




Fig. 1. Non-medical devices used in this study for an invasive airway management.

high-flow intravenous spike and drip chamber.⁸ Neill and Anderson performed a study with nine junior doctors and medical students, who were able to place a successful cricothyroidotomy just with a ballpoint pen and a scalpel blade in fourteen formalin-fixated cadavers.⁹ In a previous study of our working group we could show that a cricothyroidotomy in fresh cadavers just with a ballpoint pen is nearly impossible.¹⁰

However, there is uncertainty about whether it is possible to perform a cricothyroidotomy and maintain gas exchange using improvised non-medical devices. This study examines the ability of bystanders to place an emergency cricothyroidotomy in fresh human cadavers using only a pocket knife and a ballpoint pen.

Materials and methods

Procedures were performed on unselected, undissected fresh human cadavers from the forensic department of the University of Munich. No cadaver was older than two days. All cadavers were cooled to 8 °C (not frozen) and allowed to warm to room temperature before incision. The study was approved by the local ethical review committee under the N°336-13. The relatives of the recently deceased persons received information about the study and were asked for permission by the forensic department. Informed consent was given in all cases on the basis of the known or presumed will of the deceased. The complete cricothyroidotomy was recorded by video.

Only few ballpoint pen barrels meet the criteria for cricothyroidotomy tubes.¹¹ In a previous study the following two commonly available ballpoint pens were selected¹⁰:

- The Montblanc Masterpiece Platinum Line Classique made of black ebony with a removable metal jacket at the top. Despite the high price one of Montblanc's bestsellers worldwide (Fig. 1a).
- The Ritter-Pen O1711 Classic made of opaque plastic with a removable metal jacket at the top (Fig. 1b).

A variety of knives were available for the participants to choose freely. Skin cutting is depended on the force applied and the sharpness and length of the blade (b_1). From S. V. Hainsworth, R. J. Delaney and G. N. Ruttly¹⁹ it is known that the blunt edge radius (b_r) of a knife is most important for the penetration ability in stab injuries (Fig. 3). All knives are well-known and are distributed all over the world:

- Victorinox 1.3603 Spartan red, $b_r = 0.028$ mm, $b_1 = 5.0$ cm (Fig. 1g)
- Victorinox 0.6385 MiniChamp red, $b_r = 0.020$ mm, $b_1 = 3.5$ cm (Fig. 1f)

- Leatherman Wave, $b_r = 0.024$ mm, $b_1 = 6.0$ cm (Fig. 1e)
- Opinel N°7 stainless, $b_r = 0.032$ mm, $b_1 = 10.0$ cm (Fig. 1d)
- Opinel N°5 stainless, $b_r = 0.024$ mm, $b_1 = 5.0$ cm (Fig. 1c)

Participants of the study included 3 medical students and 1 dentistry student in their first or second preclinical year. While all of these students had anatomical training, none had experience in surgery, surgical procedures or emergency medicine. The other six participants were medical laypersons (e.g., police officer, teacher, flight attendant).

Cadavers were placed supine with their neck exposed. Before the beginning of the experimental procedure the thyroid cartilage was tested to be clearly palpable in all cadavers by the supervisors of the forensic institute (A. Huber and Ch. Braun). All participants received a 2 min scenario informing them of an emergency situation with an unconscious person with no success of mouth-to-mouth-resuscitation. They had to choose one of the pens and one of the knives and were asked to access the upper airway with these devices to establish a mouth-to-pen-resuscitation as fast as possible. They were advised to identify the thyroid cartilage as a possible landmark. No information was given concerning the exact location to start the procedure. Procedure time was defined as the time from when the participant touched one of the non-medical devices until they were happy with the placement of the pen barrel or the participant abandoned the procedure.

The primary outcome of the study was the rate of successful placement of the pen barrel within the trachea and was determined at the end by the thoracic lifting in a mouth-to-pen resuscitation. Secondary outcomes were injuries to associated anatomical structures and time to placement. The collateral damage was determined afterwards by professional preparation of the cervical structures, done by the forensic institute.

Results

The main results are summarized in Table 1.

Bystanders were an average age of 31.8 y (SD=7.3 y), and 8 of 10 were women. Cadavers were an average age of 74 (SD=7.8 y) years at death, the gender distribution was 50/50 and the average body mass index was 26.4 kg/m², whereas the neck length in average was 6.75 cm (SD= 1.339 cm). The thyroid cartilage was palpable by the supervisors in all cadavers. Eight out of ten (80%) participants performed a successful approach to the upper airway with a thoracic lifting in the mouth-to-pen resuscitation. Five participants performed a successful cricothyroidotomy and three performed an unintentional tracheostomy, but with a positive

Table 1

Results in 10 trials of cricothyroidotomy by 10 bystanders just with a pocket knife and a ballpoint pen. Outcome pos. = successful cricothyroidotomy. Outcome pos. (TT) = successful tracheotomy Vid 1: Successful mouth-to-pen resuscitation in case No. 4. Verification at an "open approach".

No	Bystander's age and profession	Bystander's gender	Procedure's duration	Pen	Knife	Cadaver specifications	Outcome	Collateral Damage
1	26, flight attendant	Female	01:30 min	Montblanc	Opinel 07	86 years, BMI 25.5, Neck: 7 cm	Pos.	Sternohyoid muscle Cricothyroid muscle Tracheal posterior
2	24, second year medical student	Female	01:10 min	Ritter C	Victorinox	76 years, BMI 31.6, Neck: 5.5 cm	Pos.	
3	32, pilot	Male	00:44 min	Montblanc	None	68 years, BMI 37.1, Neck: 3.5 cm	Neg.	Sternohyoid muscle
4	25, police officer	Male	05:50 min	Ritter C	None	86 years, BMI 25.4, Neck: 7 cm	Pos.	Sternohyoid muscle Tracheal posterior Cricoid fracture
5	40, teacher	Female	07:20 min	Ritter C	Leatherman	63 years, BMI 27.3, Neck: 7.5 cm	Pos.	Sternohyoid muscle Right thyroid gland Cricoid fracture Cartilago trachealis
6	22, second year medical student	Female	04:50 min	Montblanc	Victorinox	68 years, BMI 26, Neck 7 cm	Pos. (TT)	Sternohyoid muscle Thyroid vessel
7	28, dentistry student	Female	01:40 min	Ritter C	Opinel 07	86 years, BMI 29.4, Neck 8 cm	Pos. (TT)	Thyroid gland
8	20, craftsperson	Female	07:10 min	Montblanc	Leatherman	82 years, BMI 33.7, Neck 7 cm	Neg.	Sternomastoid muscle Cartilago trachealis Major subcutaneous vein
9	22, first year medical student	Female	07:00 min	Ritter C	Victorinox	74 years, BMI 25, Neck: 7 cm	Pos.	Cricothyroid muscle Tracheal posterior Cricoid fracture
10	23, architect	Female	03:05 min	Ritter C	Leatherman	84 years, BMI 25.7, Neck: 8 cm	Pos. (TT)	Major subcutaneous vein Tracheal posterior

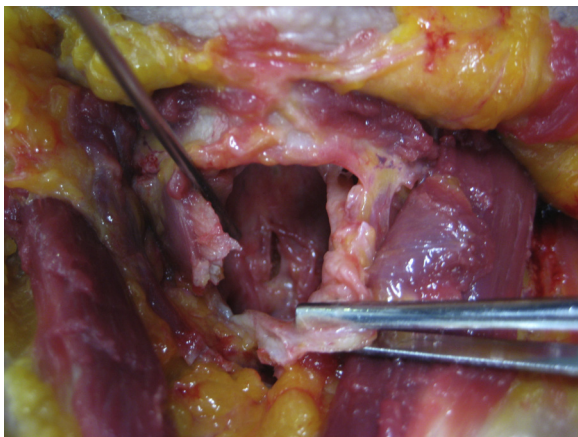


Fig. 2. Fractured cricoid cartilage due to forced insertion of a pen barrel.

outcome (ventilation was possible). Bystanders were free to choose their equipment: no one selected the Opinel N°5 or the Victorinox 0.6385 MiniChamp, probably because the blade length of these knives seemed to be too small for the procedure. In four cases the skin incision was made horizontally, in three cases vertically and in one case combined horizontally and vertically (crosswise). All bystanders tried to perform a stab incision with the knife, except N° 6 (a second year medical student), who tried several times to cut the skin with the middle of the blade horizontally (like a surgical skin incision). All participants started the procedure in the central axis beneath the thyroid cartilage. One bystander (N°3 – pilot) tried to perforate the skin and ligament just with the pen. It was impossible for him to penetrate the cricothyroid ligament, he pushed the trachea to the left side and the pen stuck on the right side paratracheally. He abandoned the procedure as unsuccessful. Another bystander (N°4 – police officer) tried the same, but was successful just with the Ritter Classic pen after three attempts and more than 5 min. He used so much force that the cricoid cartilage fractured and the ossified posterior lamina of the cricoid cartilage was partially perforated (see Fig. 2).

Injuries to anatomical structures, especially muscles, were common and are summarized in Table 1. All knives caused similar cut wounds and muscle injuries. One detail/outcome of note was that there were only small vascular injuries of veins and no oesophageal injury. In four cases cartilage structures (cricoid, tracheal cartilage) were damaged. The cricoid cartilage fractured in three cases due to forced insertion of the pen barrel with its extended cartridge.

Mean time to the end point in the successful group (8) was 243 s (SD = 157 s) and 237 s (SD = 193 s) in the unsuccessful group (2). The successful medical students (4) had a mean time of 220 s (SD = 143 s) and the successful laypersons (4) a mean time of 266 s (SD = 187 s).

Limitations

There are multiple limitations to any cadaver study. Cadavers provide a bloodless setting that might make the procedure easier. The fresh cadavers in this study all had palpable thyroid structures and were very realistic in haptic perception and rigidity. The BMI and neck length of the cadavers were very inhomogeneous. The higher the BMI and shorter the neck, the more difficult the procedure. Both unsuccessful attempts were in cadavers with a BMI >30. The medical knowledge of the bystander collective was inhomogeneous, too. The medical students and the dentistry student had some experience with skin perforations (cannulas) and more anatomical knowledge than the others. Maybe that is why they performed two real cricothyroidotomies and two tracheotomies, whereas the pilot and the craftsperson did not reach the trachea. Concerning the procedure's time, 2 out of 4 medical students were quite fast, whereas the other two were slower than some of the laypersons. In fact, one layperson (the flight attendant) was one of the quickest (1:30 min) and had a good outcome with minimal collateral damage and a successful cricothyroidotomy.

Compared to a realistic emergency setting, the conditions in this study were ideal: free access to the neck from all sides, perfect light and calm atmosphere. Basic information concerning the thyroid cartilage as the most important landmark was given to all bystanders. This basic training took about 2 min and gave the

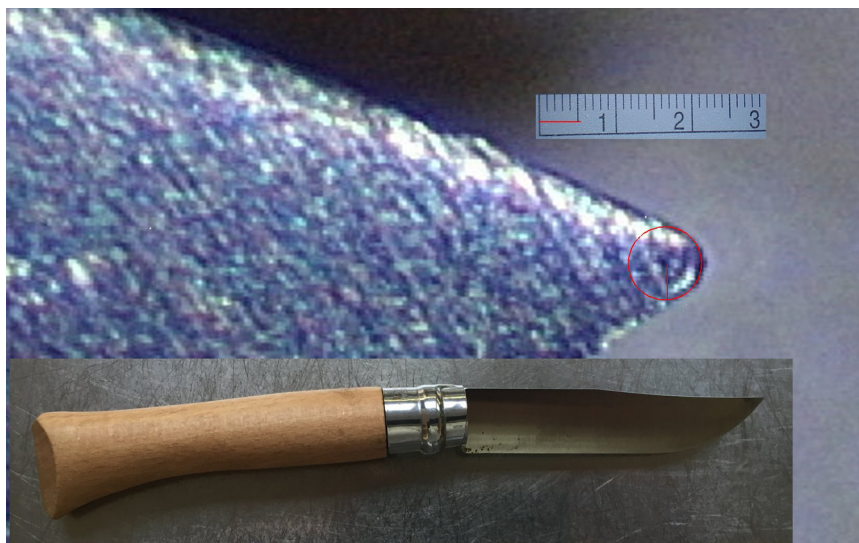


Fig. 3. Blunt edge radius of Opinel N° 7. Measured with Leica M525 F20 Stereomicroscope and Olympus EXERA III Camera.

bystander time to reconsider and thus a big advantage compared to a real life scenario.

Discussion

A ‘can’t intubate, can’t oxygenate’ situation would require improvisation in the absence of equipment, training or expertise. For a bystander and in the prehospital setting, standard medical equipment may not be immediately available. Therefore a provisional airway may need to be constructed with commonly available objects.

This is the first cadaveric study to assess the feasibility of emergency cricothyroidotomy just with improvised non-medical devices. After a very short introduction including the palpation of the thyroid cartilage, we observed that 80% of our untrained, unprepared participants were able to place a successful cricothyroidotomy or tracheotomy using only a pocket knife and a ballpoint pen barrel. Only the average procedure time in the successful group with more than 6 min was definitely too long for a standard resuscitation.¹

The skin incision (stabbing or cutting vertically or horizontally to the neck) had no influence on the outcome. 30% of bystanders tried to punctuate the trachea too far caudally and through the thyroid gland. Only in three cases a major subcutaneous or thyroid vein was perforated, which could have triggered a major bleeding in a real life model. The low risk of vessel perforation and the tendency to place the incision too far caudally are described in other (bystander) cadaveric studies.¹²

The frequency of cricoid cartilage fractures, occurring in three of 10 (30%) procedures, is somewhat higher compared with a previous cadaveric study where it occurred in three of 30 (10%) procedures.¹³ However, in that study, a wire guided technique versus a standard surgical technique was assessed using specifically designed medical equipment. The authors observed that most cartilage fractures occurred during placement of the pen barrel through the incision. After post procedural preparation we could confirm this. There are likely two reasons for this:

First, the height of the cricothyroid membrane is commonly reported as 9–10 mm¹⁴ and the external diameter of the pen used in our study was 8 mm and perhaps too large to fit through the membranes of some cadavers. Second, inexperience on the part of the participants meant that they used too much force and had difficulty

in estimating the appropriate angle to insert the barrel through the incision. In the study of Neill and Anderson an external diameter of almost 9 mm is at the upper limit of acceptable size.⁹

Rates of successful cricothyroidotomy have been similar (65–100%) in prior cadaveric studies,^{13,15–18} although these were carried out with specific airway equipment and the procedures were performed by physicians with at least some degree of training and experience.

In our study, all the medical students managed to access the upper airways with successful ventilation. In the layperson group, two participants were unsuccessful. This implies that anatomic knowledge may lead to a better outcome concerning the location.

Concerning the time needed to reach ventilation, two medical students (N°6 and 9) were slower than some of the laypersons. One layperson (N°1 – flight attendant) had the second best time and a successful cricothyroidotomy. This finding may imply that medical students without surgical experience may at least in some cases face the same problems as laypersons concerning the actual procedure.

Conclusion

In this cadaveric study, bystanders with varying medical knowledge were able to establish an emergency cricothyroidotomy or tracheotomy in 80% of the cases using only a pocketknife and a ballpoint pen. The average duration of the procedure was too long in order to perform a successful resuscitation without neurological deficits. However, no major complications (vascular or oesophageal injuries) occurred. Although a cricothyroidotomy using a pocketknife and the barrel of a pen seem a very extreme procedure for a bystander, the results of our study suggest that it is a feasible option in an emergency scenario. All ballpoint pens with a minimum inner diameter of 3 mm are suitable to perform this procedure. In order to reach a better rate of successful bystander cricothyroidotomies, the anatomical landmarks of the neck and the incision techniques should be taught in emergency courses.

Conflicts of interest

The authors declare that they have no conflicts of interest.

Authors' contributions

Christian Braun and Klaus Stelter added substantial contributions to the conception and design of the work.

Christian Braun and Astrid Huber carried out the acquisition, analysis and interpretation of data.

Ulrich Kisser drafted the work and revised it critically for important intellectual content.

All authors approved the final version of the paper.

Funding

There was no funding of this study. The MontBlanc Masterpiece Pen and the Opinel knives were bought by the Senior Author (K. Stelter). Victorinox AG provided the 1.3603 Spartan and the 0.6385 MiniChamp for free disposal for the duration of the study. Leatherman® Inc. provided two Leatherman Wave multitools for free disposal for the duration of the study.

Acknowledgment

Fabian Kriner, the lead autopsy technician of the forensic institute, provided assistance in handling of the cadavers.

Urs Wyss, Victorinox AG, provided the 1.3603 Spartan and the 0.6385 MiniChamp for free disposal for the duration of the study.

Torsten Sommer, Leatherman® Inc., provided two Leatherman Wave multitools for free disposal for the duration of the study.

Appendix A. Supplementary data

A video showing a successful mouth-to-pen resuscitation in case No.4 and verification at an "open approach" can be found in the online version at <http://dx.doi.org/10.1016/j.resuscitation.2016.10.015>.

References

- Paix BR, Griggs WM. Emergency surgical cricothyroidotomy: 24 successful cases leading to a simple 'scalpel-finger-tube' method. *Emerg Med Australas* 2012;24:23–30.
- Wang HE, Mann NC, Mears G, Jacobson K, Yealy DM. Out-of-hospital airway management in the United States. *Resuscitation* 2011;82:378–85.
- Fikkers BG, van VS, van der Hoeven JG, van den Hoogen FJ, Marres HA. Emergency cricothyrotomy: a randomised crossover trial comparing the wire-guided and catheter-over-needle techniques. *Anaesthesia* 2004;59:1008–11.
- Adams BD, Whitlock WL. Bystander cricothyroidotomy performed with an improvised airway. *Mil Med* 2002;167:76–8.
- Weiss EA, Dornier HJ. Wilderness improvisation. In: *Wilderness medicine: management of wilderness and environmental emergencies*. 3rd ed. Mosby Year Book; 1995.
- Beers MH, Berkow R. *The Merck manual of diagnosis and therapy*. 17th ed. Merck Sharpe and Dohme Research; 1999.
- Piven J, Borgenicht D, Schossig M. *Das Survival-Buch: Überleben in Extremsituationen*. Munich: Econ Ullstein; 2000.
- Platts-Mills TF, Lewin MR, Wells J, Bickler P. Improvised cricothyrotomy provides reliable airway access in an unembalmed human cadaver model. *Wilderness Environ Med* 2006;17:81–6.
- Neill A, Anderson P. Observational cadaveric study of emergency bystander cricothyroidotomy with a ballpoint pen by untrained junior doctors and medical students. *Emerg Med J* 2013;30:308–11.
- Kisser U, Braun C, Huber A, Stelter K. Bystander cricothyrotomy with ballpoint pen: a fresh cadaveric feasibility study. *Emerg Med J* 2016.
- Owens D, Greenwood B, Galley A, Tomkinson A, Woolley S. Airflow efficacy of ballpoint pen tubes: a consideration for use in bystander cricothyrotomy. *Emerg Med J* 2010;27:317–20.
- Bair AE, Chima R. The inaccuracy of using landmark techniques for cricothyroid membrane identification: a comparison of three techniques. *Acad Emerg Med* 2015;22:908–14.
- Chan TC, Vilke GM, Bramwell KJ, Davis DP, Hamilton RS, Rosen P. Comparison of wire-guided cricothyrotomy versus standard surgical cricothyrotomy technique. *J Emerg Med* 1999;17:957–62.
- Boon JM, Abrahams PH, Meiring JH, Welch T. Cricothyroidotomy: a clinical anatomy review. *Clin Anat* 2004;17:478–86.
- Benkhadra M, Lenfant F, Nemetz W, Anderhuber F, Feigl G, Fasel J. A comparison of two emergency cricothyroidotomy kits in human cadavers. *Anesth Analg* 2008;106:182–5, table.
- Eisenburger P, Laczika K, List M, et al. Comparison of conventional surgical versus Seldinger technique emergency cricothyrotomy performed by inexperienced clinicians. *Anesthesiology* 2000;92:687–90.
- Clancy MJ. A study of the performance of cricothyroidotomy on cadavers using the Minitrach II. *Arch Emerg Med* 1989;6:143–5.
- Davis DP, Bramwell KJ, Hamilton RS, Chan TC, Vilke GM. Safety and efficacy of the Rapid Four-Step Technique for cricothyrotomy using a Bair Claw. *J Emerg Med* 2000;19:125–9.
- Hainsworth SV, Delaney RJ, Ruddy GN. How sharp is sharp? Methods for quantifying the sharpness and penetrability of kitchen knives used in stabbings. *Int J Leg Med* 2008;122:281–91.