

## ORIGINAL RESEARCH

## Ventilator-assisted preoxygenation: Protocol for combining non-invasive ventilation and apnoeic oxygenation using a portable ventilator

Steven GRANT,<sup>1</sup> Faisal KHAN,<sup>1,2</sup> Gerben KEIJZERS,<sup>1,2,3</sup> Mark SHIRAN<sup>1,2</sup> and Leo MARNEROS<sup>1</sup><sup>1</sup>Gold Coast University and Robina Hospital Emergency Departments, Gold Coast, Queensland, Australia, <sup>2</sup>Griffith University, Gold Coast, Queensland, Australia, and <sup>3</sup>Bond University, Gold Coast, Queensland, Australia

## Abstract

**Objective:** To describe a simple protocol for ventilator-assisted preoxygenation (VAPOX) prior to rapid sequence intubation in the ED using a Hamilton T1 ventilator in an effort to further reduce the incidence of transient and critical hypoxaemia.

**Methods:** Ventilator-assisted preoxygenation includes the following steps; preparation for rapid sequence intubation as per institutional protocols, including departmental checklists. Hamilton T1 ventilator is setup in non-invasive spontaneous/timed mode with settings as described. The patient is optimally positioned and nasal cannula applied with an oxygen flow rate of 15 L/min. A face mask is applied with the jaw pulled forward using a two-handed thenar eminence grip and the ventilator is started. Preoxygenation occurs for 3 min. Drugs including neuromuscular blockers are administered, while the operator ensures the airway remains patent. The ventilator transitions into Pressure Controlled Ventilation once apnoea ensues. Nasal oxygen continues until endotracheal tube is successfully secured.

**Results:** We describe a case series of the first eight consecutive adult patients on who VAPOX was applied. All eight patients were clinically

deemed at high risk of oxygen desaturation. No clinically significant hypoxia occurred, and the lowest oxyhaemoglobin desaturation was 92%.

**Conclusion:** Preoxygenation using a ventilator with an open valve system may allow safe combination of non-invasive ventilation, pressure controlled ventilation and apnoeic oxygenation using nasal cannula. VAPOX may be the technique of choice to preoxygenate and apnoeic oxygenate many patients who undergo rapid sequence intubation in the ED equipped with these ventilators.

**Key words:** *airway management, anaesthesiology, emergency department, intubation, laryngoscopy, non-invasive ventilation.*

## Introduction

Rapid sequence intubation (RSI) in the ED is a high risk procedure with complications occurring in up to 40% and serious hypoxia in up to 22% of intubations, and this is associated with increased morbidity and mortality.<sup>1</sup> The fourth National Audit Project in the UK showed that one in four major

## Key findings

- A new protocol for ventilator-assisted preoxygenation (VAPOX) to facilitate intubation and ventilation is described.
- A case series of patients at risk of desaturation where VAPOX was used successfully is described.
- VAPOX is a promising technique to minimise hypoxia during rapid sequence induction.

airway complications occurred in the ED; these were more likely to lead to permanent harm or death and such events are probably under-reported.<sup>2</sup> There is limited Australian data, but two studies have shown a relatively high risk of oxygen desaturation complicating RSI, with one study from a tertiary ED in Sydney showing the incidence of hypoxia at 15.7%<sup>3</sup> and the other based in Geelong at 17.9%.<sup>4</sup>

Weingart and Levitan's influential paper<sup>5</sup> has stimulated considerable interest in blunting hypoxia during RSI, and there is some evidence that standardised approaches to RSI can reduce the incidence of adverse events.<sup>6,7</sup> We have made efforts to standardise our own approach to RSI including mandating the use of a departmentally approved checklist, introducing credentialing for medical and nursing staff who perform or assist with RSI and also maintaining an active airway registry of all RSIs performed in our ED.

Models of rates of oxyhaemoglobin desaturation have shown that even relatively minor abnormalities can be additive, resulting in rapid and serious hypoxia, and critically unwell patients

Correspondence: Faisal Khan, Gold Coast University Hospital, 1 Hospital Boulevard, Southport, Gold Coast, QLD 4215, Australia. Email: faisgold@gmail.com

Steven Grant, MBBS, DA (UK), FACEM, Senior Staff Specialist, Director Emergency Medicine Training; Faisal Khan, MBBS, BCom, Emergency Medicine and Research Registrar, Lecturer; Gerben Keijzers, MBBS, PhD, FACEM, Staff Specialist, Associate Professor; Mark Shirran, MBBS, Staff Specialist, Ambulance Medical Officer, Senior Lecturer; Leo Marneros, MBBS, Senior Staff Specialist, Director Emergency Medicine Training.

Accepted 28 October 2015

will not tolerate 45–60 s of apnoea required for traditional RSI.<sup>8</sup> In this setting, the risk of hypoxia is likely to outweigh the risk of gastric aspiration, and therefore, the avoidance of ventilation during the apnoea phase may be detrimental.

We describe a simple protocol for ventilator-assisted preoxygenation (VAPOX) prior to intubation of adult patients in the ED in an effort to further reduce the incidence of transient and critical hypoxaemia.

## Methods

Preparation for rapid sequence induction is conducted in standard fashion according to local institutional protocols including the use of a mandatory checklist (Appendix S1). The procedure is diagrammed in Figure 1.

Set up of Hamilton T1 ventilator (Hamilton Medical, Bonaduz, Switzerland):

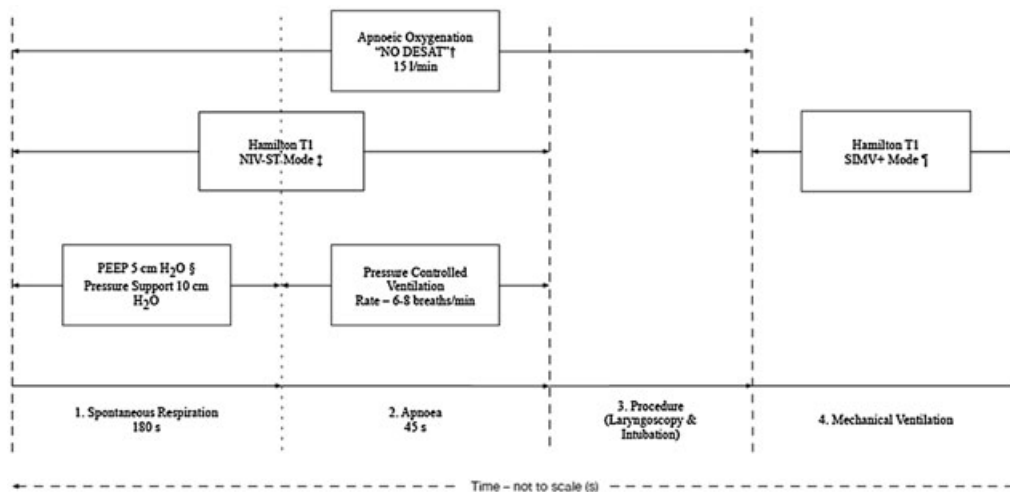
- manufacturer's recommended pre-operational tests should be completed prior to each shift including flow sensor calibration and circuit tightness testing

- the ventilator is connected to oxygen and power supply
- non-invasive spontaneous/timed mode (mode button) – NIV-ST – is selected and the following settings applied:
  - a respiratory rate of 6–8 breaths per minute
  - pressure support 10 cm water
  - positive end expiratory pressure 5 cm water
  - fraction inspired oxygen 1.0
  - expiratory trigger sensitivity 50%
  - inspiratory flow trigger 2 L/min
  - inspiratory time (Ti) 2 s
  - P-ramp 50 ms

Procedure:

- agitated or combative patients may require ketamine to tolerate the procedure – pretreat if necessary with up to 1 mg/kg intravenously, titrating to effect
- the patient is optimally positioned (ear-sternal notch to align airway) with a pillow or occipital pad and placed in a head elevated (e.g. 20°) position<sup>9</sup>
- standard nasal cannulas should be applied and the flow commenced at 15 L/min
- the ventilator circuit is connected to a standard soft style manual resuscitator face mask – it is recommended

- that a capnograph be inserted between face mask and flow sensor
- the ventilator should now be started – press 'start ventilation'
- the face mask is applied with a two-handed thenar eminence-type grip (Fig. 2) and preoxygenation commences for 3 min
- drugs including neuromuscular blockers (rocuronium is most frequently used at our institution, and cricoid pressure is not routinely applied) are pushed, and the operator ensures the jaw is pulled forward with a two-handed thenar eminence grip
- end-tidal CO<sub>2</sub> trace is inspected to confirm airway patency and alveolar gas exchange is occurring
- ventilator transitions to pressure controlled ventilation (PCV+) once apnoea ensues
- intubation commences after at least 45 s (assuming rocuronium dose is 1.2 mg/kg)
- nasal oxygenation continues until endotracheal tube is successfully placed
- ventilator is then changed to a conventional ventilation mode, for example, controlled mandatory ventilation (CMV+) or synchronised intermittent



†Nasal Oxygen During Efforts to Secure A Tube

‡Noninvasive – spontaneous/timed

§Positive End Expiratory Pressure

¶Synchronised intermittent mandatory ventilation

**Figure 1.** Ventilator-assisted preoxygenation (VAPOX) technique combining nasal oxygen at 15 L/min, non-invasive ventilation and pressure controlled ventilation.

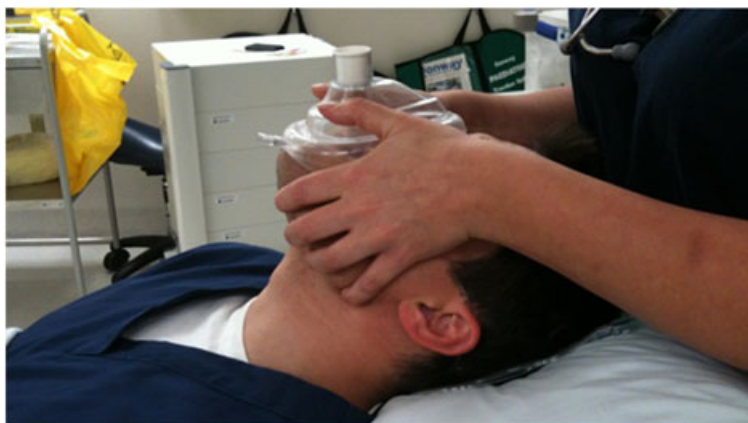

Figure 2. *Thenar eminence type grip.*

mandatory ventilation (SIMV+) and post-ventilation care continues

### Case examples

Table 1 and Figure 3 refer to a series of eight patients who were assessed as high risk of oxyhaemoglobin desaturation prior to RSI who received VAPOX. These patients were all adults and RSI supervised by one of the authors. In each case, it was difficult to achieve high-oxygen saturations on a non-rebreather face mask, and/or the patient was judged to be high risk on clinical grounds. Patient 6

was experiencing a drug induced psychosis and required ketamine prior to VAPOX. Patient 7 was significantly hypoxic after a suspected aspiration associated with a decreased level of consciousness following an intracranial haemorrhage. The best oxyhaemoglobin saturation was 88% at 15 L/min on a non-rebreather mask and this improved to 100% post-VAPOX. The first attempt at intubation resulted in inadvertent oesophageal intubation that was immediately recognised and the patient intubated successfully on the second attempt with oxyhaemoglobin saturations of 93%

immediately post-intubation. In no case did clinically significant hypoxaemia occur and the lowest oxyhaemoglobin desaturation was 92% (Case 8).

### Discussion

In 2012, the Gold Coast Health Service District EDs acquired 16 new Hamilton T1 ventilators. These new ventilators featured a biphasic design and an open valve system capable of providing both non-invasive ventilation and mechanical ventilation via the same coaxial circuit. This allowed the possibility of using non-invasive ventilation via a standard manual resuscitator face mask for preoxygenation and continuing with mechanical ventilation with the same circuit after the airway is secured with an endotracheal tube.

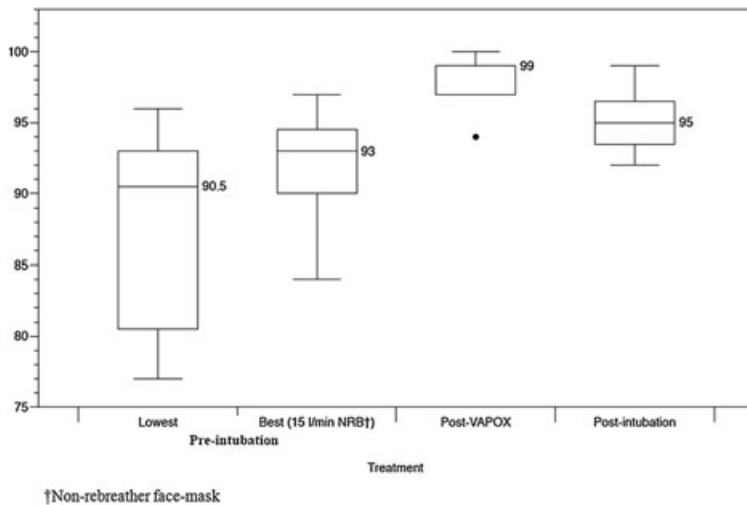
### Non-invasive ventilation for preoxygenation

Utilisation of continuous positive airway pressure (CPAP) and/or NIV to increase mean airway pressure and provide more effective preoxygenation is well reported in elective surgical patients with both normal and increased body mass indices.<sup>10-14</sup>

TABLE 1. *Demographics, indications and oxygen saturations of eight cases treated with VAPOX*

Demographics			Indications		Oxygen saturations (%)			
Case	Age (years)	Sex	Clinical information	Glasgow coma score	Pre-intubation			
					Lowest	Best (15 L/min non-rebreather)	Post VAPOX	Post intubation
1	89	Male	Post VF arrest + ROSC	9 E3 V1 M5 Agitated + combative	82	92	97	95
2	45	Female	Post VF arrest + ROSC	11 E4 M5 Agitated + combative	92	94	99	97
3	57	Male	Status epilepticus	3 E1 V1 M1	94	95	99	96
4	24	Male	Polypharmacy overdose	12 E3 V4 M5 Agitated + combative	91	94	99	95
5	68	Male	Post VF arrest + ROSC	11 E4 V2 M5 Agitated + combative	90	92	97	94
6	30	Male	Drug induced psychosis	13 E3 V4 M6 Agitated + combative	96	97	99	99
7	60	Male	Altered level consciousness	3 E1 V1 M1	77	88	100	93
8	65	Male	Traumatic intracranial bleed	3 E1 V1 M1	79	84	94	92

ROSC, return of spontaneous circulation; VAPOX, ventilator-assisted preoxygenation; VF, ventricular fibrillation.



**Figure 3.** Box and whisker plot for oxygen saturations (%) in eight cases pre-ventilator-assisted preoxygenation (VAPOX) and post-VAPOX.

A small randomised controlled trial from two French intensive care units demonstrated that non-invasive ventilation could be more effective to preoxygenate critically ill patients with respiratory failure, increase oxygen saturations prior to intubation and reduce oxygen desaturation during laryngoscopy with benefits persisting for up to 30 min post-intubation.<sup>15</sup> This study used pressure support titrated to an expiratory tidal volume of 7–10 mL/kg compared with a standard bag-valve-mask device, and there was no increase in aspiration or new infiltrates on chest radiography.

Rapid sequence intubation can be broken down into four stages:

1. Preoxygenation
2. Onset of apnoea and muscle relaxation
3. Procedure (laryngoscopy and intubation)
4. Post-ventilation care

### Ventilator-assisted preoxygenation

Ventilator-assisted preoxygenation allows preoxygenation via simple face mask with the benefits of both CPAP and NIV with 100% oxygen. Judicious use of ketamine for sedation will allow even the most uncooperative patient to tolerate the procedure.<sup>16,17</sup>

Once drugs are pushed and a neuromuscular blocking agent is administered, the patient will transition into the apnoeic phase. In NIV-ST mode, we have selected a rate of 6–8 breaths per minute, positive end

expiratory pressure of 5 cm water and a pressure support of 10 cm water (total pressure of 15 cm water). Using this mode and a rate of 8 breaths per minute (one breath every 7.5 s), the ventilator will seamlessly transition in to a pressure controlled mode (delivering a maximum pressure of 15 cm water) after 7.5 s of apnoea. Gentle face mask ventilation during the apnoeic period continues without the need for any intervention by the operator. It is highly recommended to have a capnograph between the mask and the flow sensor that confirms the airway is patent and that alveolar gas exchange is occurring especially after the paralytic is pushed and when apnoea ensues. It is also important to note that unlike conventional use of NIV, this is a ‘hands on’ technique and jaw thrust must be performed to maintain airway patency especially as muscle relaxation occurs.

### Pressure considerations

Several older studies suggest peak inspiratory pressures of less than 20 cm are less likely to cause gastric distention as detected by auscultation.<sup>18–21</sup> A recent study using doppler ultrasound and measurements of expiratory tidal volumes during face-mask ventilation in non-paralysed patients has shown small amounts of air are detectable entering the stomach at 15 cm water pressure but also provides adequate tidal volumes without causing any statistically significant increase in antral cross-sectional area.<sup>22</sup> It should

also be noted that modern methods of measuring lower oesophageal sphincter tone using solid state manometry have shown that the combination of intermittent positive pressure ventilation and rocuronium does not decrease barrier pressure.<sup>23</sup> This is important in our ED as rocuronium is the preferred neuromuscular blocking agent and cricoid pressure is infrequently used. The chosen ventilator settings are therefore unlikely to cause significant gastric distention or increase the risk of gastric aspiration.

### Providing ventilation during the apnoea phase

The practice of using modified or controlled RSI and providing facemask ventilation through the apnoeic phase is common,<sup>24</sup> and modified RSI using gentle face-mask ventilation during the apnoeic period is now standard operating procedure for the Queensland Ambulance Service.<sup>25</sup> Additionally, the incidence of desaturation events in an Air Medical Service in California was markedly reduced by a protocol that included bag valve mask ventilation through the apnoeic phase without any increase in self-reported aspiration events.<sup>26</sup> A Canadian literature review on rapid sequence induction concluded there was no evidence that traditional rapid sequence induction reduced the incidence of pulmonary aspiration and also that routine avoidance of bag-valve mask ventilation was not recommended.<sup>27</sup> The benefits of providing gentle mask ventilation with a pressure limiting valve of 12 cm water, avoiding cricoid pressure and using a non-depolarising neuromuscular blocker were recently demonstrated in a case series of over a 1000 children, with a very low incidence of hypoxia, and no incidence of aspiration.<sup>28</sup>

### Advantages of using a ventilator to provide preoxygenation

Using a ventilator to provide breaths via a mask may confer other advantages over human operators. Peak airway pressures are likely to be lower,<sup>29</sup> and use of a ventilator may avoid excessive respiratory rates and over-ventilation as previously documented in professional rescue personnel who



delivered an average of 30 breaths per minute during CPR for out of hospital cardiac arrest patients.<sup>30</sup> Use of a ventilator also removes the temptation to use a one-handed 'EC type grip' and encourages the use of a two-handed technique, which provides superior mask seal and ventilation even for experienced anaesthetists.<sup>31</sup> A two-handed thenar eminence grip enables more effective mask ventilation for providers who less often perform face mask ventilation and is the preferred method in our department.<sup>32</sup> Two Swiss studies, one with patients of normal BMI, and the other with BMI > 35 kg/m<sup>2</sup>, also demonstrated effective use of a ventilator and face mask to provide CPAP for preoxygenation and pressure controlled ventilation prior to intubation resulting in prolonged safe apnoea time.<sup>13,14</sup>

### Compensation for poor mask seal

Suggested use of non-rebreather masks at high-oxygen flow rates of up to 60 L/min over bag-valve-mask systems for preoxygenation<sup>5,33</sup> are based on concerns that inadequate mask seals are frequently obtained with face masks. It also assumes that standard flow meters can deliver these gas flows when turned up to maximum flow, resulting in high fractions of inspired oxygen concentration. This has not been shown to be correct with standard flow meters at our institution with maximum flow rates consistently documented at just over 19 L/min. It is likely that patients with significant respiratory distress will generate inspiratory flow rates well beyond this resulting in a low fraction of inspired oxygen concentration making this a poor choice in patients with potentially high inspiratory flow rates. In contrast, the T1 ventilators can compensate for very large leaks in non-invasive modes of up to 260 L/min<sup>34</sup> even in cases where a poor face mask seal is obtained for any reason.

### Combining with 'nasal oxygen during efforts securing a tube'

Ramachandan first described the use of apnoeic oxygenation using nasal cannulas to prolong safe apnoea times in 30 bariatric patients undergoing general anaesthesia,<sup>35</sup> and this has

subsequently been popularised by Levitan as 'nasal oxygen during efforts to secure a tube' when used for emergency RSI.<sup>36</sup> Recently, a Sydney retrieval service demonstrated a lower incidence of desaturation in patients who received nasal oxygenation during prehospital RSI,<sup>37</sup> and this technique has also been incorporated into our local RSI protocol. When nasal oxygen is used under face masks connected to a T1 ventilator in non-invasive modes at a flow rate of 15 L/min, it is unlikely to cause any significant rise in pressure as the T1 features an open valve system. However, expiratory tidal volumes will be inaccurate and nuisance alarms may be generated. In our experience of combining nasal oxygen and NIV, we have not noted any significant rise in airway pressure or any high pressure alarms. It is an option to only turn the oxygen flow on after face mask removal immediately prior to intubation; however, this generates an additional step, which may be easily omitted or forgotten.

In our limited experience, combining NIV and apnoeic oxygenation using this protocol offers significant advantages over conventional bag-valve-mask preoxygenation, it is simple and easy to apply in the emergency setting, and appears to be safe and effective in appropriately selected adult patients. We are unable to comment on the use of other ventilators prevalent in Australian EDs and our experience of this technique is limited to the Hamilton T1 ventilator.

### Conclusion

Preoxygenation using a ventilator with an open valve system may allow safe combination of non-invasive ventilation, pressure controlled ventilation and apnoeic oxygenation using nasal cannulas. Although there are theoretical advantages supporting the use of VAPOX, more experience with this technique and active audit, or possibly a randomised controlled trial will reveal if it can be applied to a broader range of patients and significantly reduce the incidence of transient and critical hypoxaemia in emergency RSI. If the technique is shown to be safe and effective across a wide range of patients, it may be the technique of

choice to preoxygenate many patients who undergo RSI in the ED equipped with these ventilators.

### Competing interests

GK is a section editor for *Emergency Medicine Australasia*. The authors declare that they have no affiliation with Hamilton Medical and have no conflicts of interest, financial or otherwise.

### References

1. Simpson GD, Ross MJ, McKeown DW, Ray DC. Tracheal intubation in the critically ill: a multi-centre national study of practice and complications. *Br. J. Anaesth.* 2012; 108: 792–9.
2. Cook TM, Woodall N, Harper J, Benger J. Major complications of airway management in the UK: results of the Fourth National Audit Project of the Royal College of Anaesthetists and the Difficult Airway Society. Part 2: intensive care and emergency departments. *Br. J. Anaesth.* 2011; 106: 632–42.
3. Fogg T, Annesley N, Hitos K, Vassiliadis J. Prospective observational study of the practice of endotracheal intubation in the emergency department of a tertiary hospital in Sydney, Australia. *Emerg. Med. Australas.* 2012; 24: 617–24.
4. Phillips L, Orford N, Ragg M. Prospective observational study of emergent endotracheal intubation practice in the intensive care unit and emergency department of an Australian regional tertiary hospital. *Emerg. Med. Australas.* 2014; 26: 368–75.
5. Weingart SD, Levitan RM. Preoxygenation and prevention of desaturation during emergency airway management. *Ann. Emerg. Med.* 2012; 59: 165–75 e1.
6. Sherren PB, Tricklebank S, Glover G. Development of a standard operating procedure and checklist for rapid sequence induction in the critically ill. *Scand. J. Trauma Resusc. Emerg. Med.* 2014; 22: 41.
7. Jaber S, Jung B, Corne P *et al.* An intervention to decrease complications related to endotracheal intubation in the intensive care unit: a prospective, multiple-center study. *Intensive Care Med.* 2010; 36: 248–55.

8. Farmery AD, Roe PG. A model to describe the rate of oxyhaemoglobin desaturation during apnoea. *Br. J. Anaesth.* 1996; **76**: 284–91.
9. Levitan RM, Mechem CC, Ochroch EA, Shofer FS, Hollander JC. Head-elevated laryngoscopy position: improving laryngeal exposure during laryngoscopy by increasing head elevation. *Ann. Emerg. Med.* 2003; **41**: 322–30.
10. Cressey DM, Berthoud MC, Reilly CS. Effectiveness of continuous positive airway pressure to enhance pre-oxygenation in morbidly obese women. *Anaesthesia* 2001; **56**: 680–4.
11. Delay JM, Sebbane M, Jung B *et al.* The effectiveness of noninvasive positive pressure ventilation to enhance preoxygenation in morbidly obese patients: a randomized controlled study. *Anesth. Analg.* 2008; **107**: 1707–13.
12. Futier E, Constantin J-M, Pelosi P *et al.* Noninvasive ventilation and alveolar recruitment maneuver improve respiratory function during and after intubation of morbidly obese patients: a randomized controlled study. *Anesthesiology* 2011; **114**: 1354–63.
13. Gander S, Frascarolo P, Suter M, Spahn DR, Magnusson L. Positive end-expiratory pressure during induction of general anesthesia increases duration of nonhypoxic apnea in morbidly obese patients. *Anesth. Analg.* 2005; **100**: 580–4.
14. Herriger A, Frascarolo P, Spahn DR, Magnusson L. The effect of positive airway pressure during pre-oxygenation and induction of anaesthesia upon duration of non-hypoxic apnoea. *Anaesthesia* 2004; **59**: 243–7.
15. Baillard C, Fosse JP, Sebbane M *et al.* Noninvasive ventilation improves preoxygenation before intubation of hypoxic patients. *Am. J. Respir. Crit. Care Med.* 2006; **174**: 171–7.
16. Weingart SD, Trueger NS, Wong N, Scofi J, Singh N, Rudolph SS. Delayed sequence intubation: a prospective observational study. *Ann. Emerg. Med.* 2015; **65**: 349–55.
17. Weingart SD. Preoxygenation, reoxygenation, and delayed sequence intubation in the emergency department. *J. Emerg. Med.* 2011; **40**: 661–7.
18. Ho-Tai LM, Devitt JH, Noel AG, O'Donnell MP. Gas leak and gastric insufflation during controlled ventilation: face mask versus laryngeal mask airway. *Can. J. Anaesth.* 1998; **45**: 206–11.
19. Lawes EG, Campbell I, Mercer D. Inflation pressure, gastric insufflation and rapid sequence induction. *Br. J. Anaesth.* 1987; **59**: 315–8.
20. Ruben H, Knudsen EJ, Carugati G. Gastric inflation in relation to airway pressure. *Acta Anaesthesiol. Scand.* 1961; **5**: 107–14.
21. Weiler N, Heinrichs W, Dick W. Assessment of pulmonary mechanics and gastric inflation pressure during mask ventilation. *Prehosp. Disaster Med.* 1995; **10**: 101–5.
22. Bouvet L, Albert ML, Augris C *et al.* Real-time detection of gastric insufflation related to facemask pressure-controlled ventilation using ultrasonography of the antrum and epigastric auscultation in nonparalyzed patients: a prospective, randomized, double-blind study. *Anesthesiology* 2014; **120**: 326–34.
23. Ahlstrand R, Thorn SE, Wattwil M. High-resolution solid-state manometry of the effect of rocuronium on barrier pressure. *Acta Anaesthesiol. Scand.* 2011; **55**: 1098–105.
24. Ehrenfeld JM, Cassidy EA, Forbes VE, Mercaldo ND, Sandberg WS. Modified rapid sequence induction and intubation: a survey of United States current practice. *Anesth. Analg.* 2012; **115**: 95–101.
25. Queensland Ambulance Service. Clinical practice procedures: airway management/rapid sequence induction. 2015. [Cited 10 May 2015.] Available from URL: [https://ambulance.qld.gov.au/%5Cdocs%5CClinical%5Ccpp%5CCPP\\_Rapid%20sequence%20induction.pdf](https://ambulance.qld.gov.au/%5Cdocs%5CClinical%5Ccpp%5CCPP_Rapid%20sequence%20induction.pdf)
26. Davis DP, Lemieux J, Serra J, Koenig W, Aguilar SA. Preoxygenation reduces desaturation events and improves intubation success. *Air Med. J.* 2015; **34**: 82–5.
27. Neilipovitz DT, Crosby ET. No evidence for decreased incidence of aspiration after rapid sequence induction. *Can. J. Anaesth.* 2007; **54**: 748–64.
28. Neuhaus D, Schmitz A, Gerber A, Weiss M. Controlled rapid sequence induction and intubation – an analysis of 1001 children. *Paediatr. Anaesth.* 2013; **23**: 734–40.
29. von Goedecke A, Voelckel WG, Wenzel V *et al.* Mechanical versus manual ventilation via a face mask during the induction of anesthesia: a prospective, randomized, crossover study. *Anesth. Analg.* 2004; **98**: 260–3 table of contents.
30. Aufderheide TP, Lurie KG. Death by hyperventilation: a common and life-threatening problem during cardiopulmonary resuscitation. *Crit. Care Med.* 2004; **32**: S345–51.
31. Joffe AM, Hetzel S, Liew EC. A two-handed jaw-thrust technique is superior to the one-handed “EC-clamp” technique for mask ventilation in the apneic unconscious person. *Anesthesiology* 2010; **113**: 873–9.
32. Gerstein NS, Carey MC, Braude DA *et al.* Efficacy of facemask ventilation techniques in novice providers. *J. Clin. Anesth.* 2013; **25**: 193–7.
33. Earl JW. Delivery of high FiO<sub>2</sub>. Abstract presentation at American Association of Respiratory Care Annual Conference 2003 Open Forum Abstract. 2012 [Updated 2003; Cited 2012.] Available from URL: <http://www.rcjournal.com/abstracts/2003/index.cfm>
34. Hamilton Medical. *Operator's Manual Hamilton T1*. Switzerland: Bonduz; 2014. [Cited 23 Jun 2015.] Available from URL: <https://www.hamilton-medical.com>
35. Ramachandran SK, Cosnowski A, Shanks A, Turner CR. Apneic oxygenation during prolonged laryngoscopy in obese patients: a randomized, controlled trial of nasal oxygen administration. *J. Clin. Anesth.* 2010; **22**: 164–8.
36. Levitan RM. NO DESAT! Nasal oxygen during efforts securing a tube. *Emergency Physicians Monthly*. 2010. [Updated 9 Dec 2010; cited 28 Mar 2015.] Available from URL: <http://www.epmonthly.com/archives/features/no-desat/>
37. Wimalasena Y, Burns B, Reid C, Ware S, Habig K. Apneic oxygenation was associated with decreased desaturation rates during rapid sequence intubation by an Australian helicopter emergency medicine service. *Ann. Emerg. Med.* 2015; **65**: 371–6.

## Supporting information

Additional supporting information may be found in the online version of this article at the publisher's web site:

**Appendix S1** Adult emergency intubation checklist.