



Contents lists available at ScienceDirect

## American Journal of Emergency Medicine

journal homepage: [www.elsevier.com/locate/ajem](http://www.elsevier.com/locate/ajem)The American Journal of  
Emergency Medicine

Therapeutic

## Tips and Troubleshooting for Use of the GlideScope Video Laryngoscope for Emergency Endotracheal Intubation<sup>☆</sup>

Emily R. Bacon, MD, MS<sup>a,b,\*</sup>, Michael P. Phelan, MD<sup>a</sup>, D. John Doyle, MD, PhD<sup>c,d,e</sup><sup>a</sup> Emergency Services Institute, Cleveland Clinic Health Systems, Cleveland, OH<sup>b</sup> Case Western Reserve University–MetroHealth Medical Center, Cleveland, OH<sup>c</sup> Case Western Reserve University, Cleveland, OH<sup>d</sup> Department of General Anesthesiology, Cleveland Clinic Foundation, Cleveland, OH<sup>e</sup> Department of General Anesthesiology, Anesthesiology Institute, Cleveland Clinic Abu Dhabi, Abu Dhabi, United Arab Emirates

## ARTICLE INFO

## Article history:

Received 31 March 2015

Received in revised form 2 May 2015

Accepted 7 May 2015

Available online xxxxx

## ABSTRACT

Video laryngoscopy (VL) is still a relatively novel advancement in airway management that offers many potential benefits over direct laryngoscopy. These advantages include decreased time to intubation in difficulty airways, unique opportunities in teaching as the video screen allows for real time teaching points, increased first pass success, particularly with novice operators, and decreased cervical spine motion during intubation. Despite the advantages, the intubation procedure itself has some subtle but significant differences from direct laryngoscopy that change the expected motion as well as troubleshooting techniques, which might discourage the use of the GlideScope by practitioners less familiar with the product. With the hope of generating confidence in the video laryngoscopy procedure, we have compiled some basic tips that we have found helpful when intubating with the GlideScope. These tips include inserting the blade to the left of midline to improve space allowed for the endotracheal tube itself, backing the scope up a small amount to improve the view, holding the tube close to the connector to improve maneuverability, and withdrawing the tube with your thumb to improve advancement through the cords. We hope that, with these tips, in conjunction with ample practice, clinicians can gain comfort and experience with all the tools at our disposal in an effort to provide the best possible care for our patients.

© 2015 Elsevier Inc. All rights reserved.

## 1. Introduction

Emergency airway management is one of the cornerstones of emergency medicine procedural skills, with the standard of definitive emergency airway control being endotracheal (ET) intubation. The procedure of ET intubation has a long history, with reports of blind intubations with metal and leather tubes cited in the medical literature as far back as the 1700s. Interestingly, development of a method to visualize the larynx itself is credited not to a physician but to a voice professor, Manuel Garcia, in London during the middle of the 19th century. Garcia described using a series of mirrors to visualize his own trachea and vocal cords, performing the first indirect laryngoscopy [1]. The credit for this discovery is somewhat controversial, however, as other sources cite a young medical student named Benjamin Guy Babington in 1829 as the first to use mirrors to allow visualization around the tongue and of the larynx [2,3]. In either case, the technique was advanced by Alfred

Kirstein in Berlin, Germany, at the end of the 19th century. Kirstein borrowed ideas from esophageal endoscopy to develop the “autoscope,” the first documented tool that allowed direct visualization of the larynx using a headlamp for light. Chevalier Jackson modified this device to include a tungsten light bulb on the distal end. Advances continued throughout the 20th century, with improvements in both adjuvant medications and the blades themselves. In the 1940s, Robert Miller and Sir Robert Macintosh described the blades that carry their names and are still widely used today [1]. Despite decades of advances and its remarkable efficacy, direct laryngoscopy (DL) still left cases with inadequate glottic exposure, and it is these cases that led to the development of, or return to, indirect laryngoscopy with video laryngoscopes.

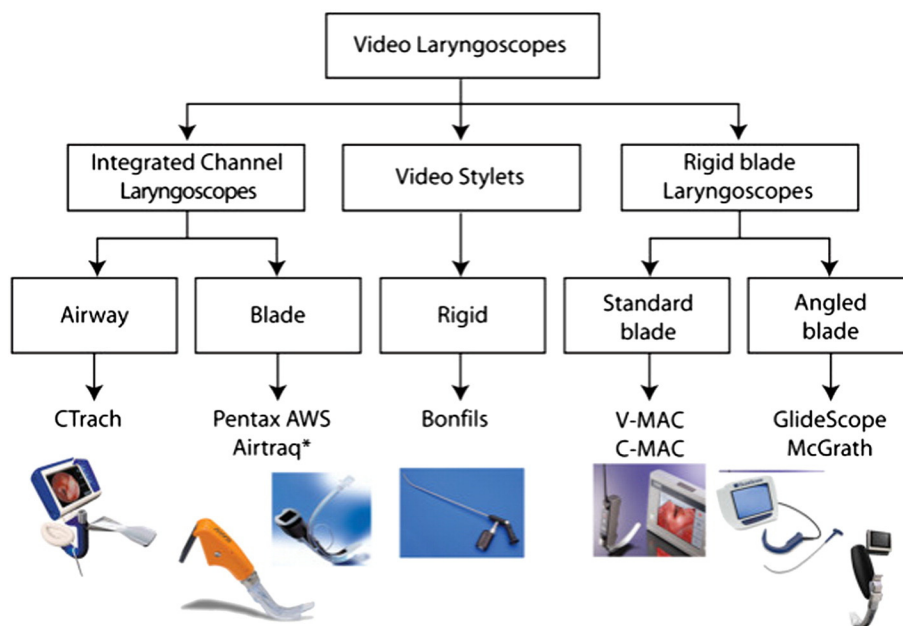
## 2. Video laryngoscopes

Video laryngoscopes consist of a laryngoscope blade with a video camera fixed near the distal end of the blade (Fig. 1). The camera allows the glottic view to be projected to a video screen, allowing the clinician to look past the curvature of the tongue and into the larynx without the required alignment of the pharyngeal, laryngeal, and tracheal axes. Although DL is by no means obsolete, video laryngoscopy (VL) has several potential advantages over it. First, VL can be a safe choice when approaching an expected difficult airway, as it can improve the view of the glottic opening and decrease the time needed for intubation [4].

<sup>☆</sup> Financial and Competing Interests Disclosure: The authors have no relevant affiliations or financial involvement with any organization or entity with a financial interest in or financial conflict with the subject matter or materials discussed in the manuscript. This includes employment, consultancies, honoraria, stock ownership or options, expert testimony, grants or patents received or pending, or royalties.

\* Corresponding author at: Department of Emergency Medicine, MetroHealth Medical Center, 2500 Metrohealth Dr, Cleveland, OH, 44109.

E-mail address: [ebacon@metrohealth.org](mailto:ebacon@metrohealth.org) (E.R. Bacon).



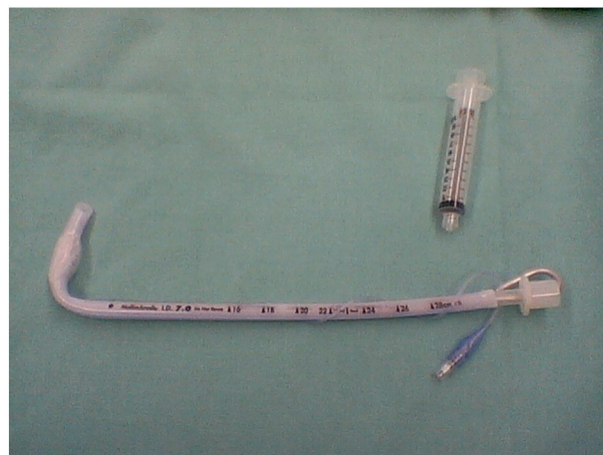
**Fig. 1.** A classification of video laryngoscopic devices. In this system, video laryngoscopes are classified according their shape and form. Left, Video laryngoscopes with an integrated channel (to guide placement of the ET tube). Middle, Video laryngoscopes taking the form of a video stylet (with the ET tube placed around the device). Right, Video laryngoscopes with a rigid blade (without a channel, the ET tube requiring an independent stylet to guide placement). From Healy DW, Maties O, Hovord D, Kheterpal S. A systematic review of the role of videolaryngoscopy in successful orotracheal intubation. *BMC Anesthesiol.* 2012;12:32. Copyright 2012 Healy et al; licensee BioMed Central Ltd. This is an Open Access article distributed under the terms of the Creative Commons Attribution License (<http://creativecommons.org/licenses/by/2.0>), which permits unrestricted use, distribution, and reproduction in any medium, provided the original work is properly cited.

Second, a video laryngoscope provides a unique opportunity for teaching, as the supervising practitioner is able to see what the learners see as they attempt to intubate. This provides the opportunity for direct feedback, real-time teaching points, and discussion of the visualized anatomy. Moreover, although the literature has been mixed, several studies have pointed to advantages of VL over DL when it comes to first-past success, particularly for novices and less experienced operators [5–9]. Beyond the act of teaching, the ability for more than 1 practitioner to see the procedure allows more easily directed laryngeal manipulation, ensuring that the ET tube passes through the vocal cords appropriately. In addition, VL requires less force and repositioning, which may lead to less cervical spine motion during intubation, an advantage of some significance in trauma patients [10,11].

For whatever reason VL is chosen, once the decision is made, the next task is to decide which device to use. The 2 most widely used video laryngoscopes are the GlideScope (Verathon Medical, Bothell, WA) and the C-MAC (Karl Storz, Tuttlingen, Germany). Both come with a variety of blade shapes and styles designed to meet the needs for nearly any intubation. The original GlideScope Advanced Video Laryngoscope had a standard hyperangulated blade, with a 60° curvature intended to improve glottic exposure in difficult airways. The theory behind the improved exposure is that the angulated nature of the blade allows an easy glottic view and positions the ET tube more anteriorly, which is superior for use in situations in which the pharyngeal, laryngeal, and tracheal axes cannot be aligned (for example, in patients with airway swelling and obstruction and those requiring cervical spine immobilization) [12,13]. This hyperangulated shape necessitates the use of a correspondingly curved stylet, the GlideRite stylet, to guide the ET tube to the laryngeal inlet. Some clinicians prefer malleable stylets over the rigid GlideRite stylet provided by the manufacturer. An alternative in this case is to use a stylet in the shape of a “hockey stick” where a 90° angle is created 8 cm from the distal tip of the ET tube to ensure that the tube is directed anteriorly enough to enter the glottis (Fig. 2) [14,15].

On the other hand, GlideScope’s competitor, C-MAC, was initially marketed with a video-capable Macintosh blade, now called the

standard C-MAC blade. Proponents of the C-MAC blade argue that the familiar Macintosh shape allows the use of DL in the event that video fails and provides a feel similar to that of DL, allowing easier use. It is well recognized that both styles have advantages and disadvantages, and both companies now offer similar blades. In 2010, C-MAC produced the C-MAC D blade with a 60° angulation for anticipated difficult airways, with the advantages described above. Similarly, GlideScope recently produced the titanium T3 and T4 blades that feature video capability with the standard Macintosh shape. Both companies offer equipment for a range of patient ages and sizes as well as single use and reusable forms. So far, direct comparisons between the 2 tools have not shown any clear advantage of one over another [16], so the choice falls to practitioner or institutional preference.



**Fig. 2.** Endotracheal tube bent at a 90° angle (“hockey stick”) created 8 cm from the distal end of the ET tube using a malleable stylet.

### 3. GlideScope Video Laryngoscope

We acknowledge the advantages of both types of video laryngoscopes, but our institutional preference is the GlideScope. Because of its hyperangulated blade, the intubation procedure with this instrument has some subtle but significant differences from DL. The difference in the shape of the blade and the stylet changes the expected motion as well as troubleshooting techniques, which might discourage the use of the GlideScope by practitioners less familiar with the product. With the hope of generating confidence in the VL procedure, we have compiled some basic tips that we have found helpful when intubating with the GlideScope.

### 4. Tips and troubleshooting for use of the GlideScope

#### 4.1. Tip 1. Practice makes perfect!

Use the GlideScope (or other VL) for easy, routine cases until you are very comfortable with it. That way, when you need it for a particularly difficult airway case, you will already be familiar with the mechanics of the device.

#### 4.2. Tip 2. You have a great view but cannot get the tube into the mouth. Try shifting to the left

Although there is often ample space for the laryngoscope and ET tube, sometimes, space is limited, especially in those with small mouths. Although it is generally well accepted that a midline approach is important in achieving the optimal laryngeal view [17], situations arise in which a midline approach makes passage of the ET tube into the mouth difficult. In these situations, try to insert the GlideScope slightly to the left of midline to ensure adequate room to the right of the device to get the tube into the mouth. Alternatively, once the GlideScope is in the pharynx and the laryngeal view is obtained, one can also try to insert the blade to the left corner of the mouth [18] or shift the handle to the

left to allow passage [19]. This can be particularly important when a large-diameter tube is being inserted.

#### 4.3. Tip 3. If the “best view” is not good enough to pass the tube through the cords, you’re probably too close. Try backing up

Novice users often report having a wonderful view of the cords but then have the unanticipated problem of not being able to get the tube into the cords. Paradoxically, maximizing the size of the glottic view with full and complete advancement of the GlideScope into the oropharynx might adversely impact the ease of subsequent intubation. If the pharynx is entered too deeply, the initial mechanics may be suboptimal when trying to pass the ET tube into the larynx and through the cords; backing the scope up 1 to 2 cm often resolves this issue. VL allows the “eye” of the practitioner to be directly in front of the glottic opening, which is often too close. Full advancement of the laryngoscope sometimes makes the view too narrow, making it actually more difficult to intubate. Backing up the scope a short distance expands the visual field and allows better glottic exposure (Fig. 3). Moreover, with this positioning of the device, the “approach angle” of the ET tube is often more amenable to passage of the tube into the glottis. The position that provides the best glottic view is generally not the position that makes intubation the easiest: a “good enough” view is usually the most favorable.

#### 4.4. Tip 4. Hold the tube closer to the connector (farther from the patient’s mouth) to gain greater maneuverability

Most practitioners are accustomed to holding the ET tube midway between the tip and the connector. The modified acute angle of the ET tube (when using a GlideScope VL) often causes difficulty and frustration when trying to pass its tip into the cords. If this occurs, try holding the tube more proximally (farther from the patient’s mouth), close to the connector, and allow the end to act as a pivot point (the midportion of the ET tube serves as this point in DL). By holding the tube more proximally, you can achieve much greater motion at the distal end (where the balloon is located) with even small movements. Subtle movements

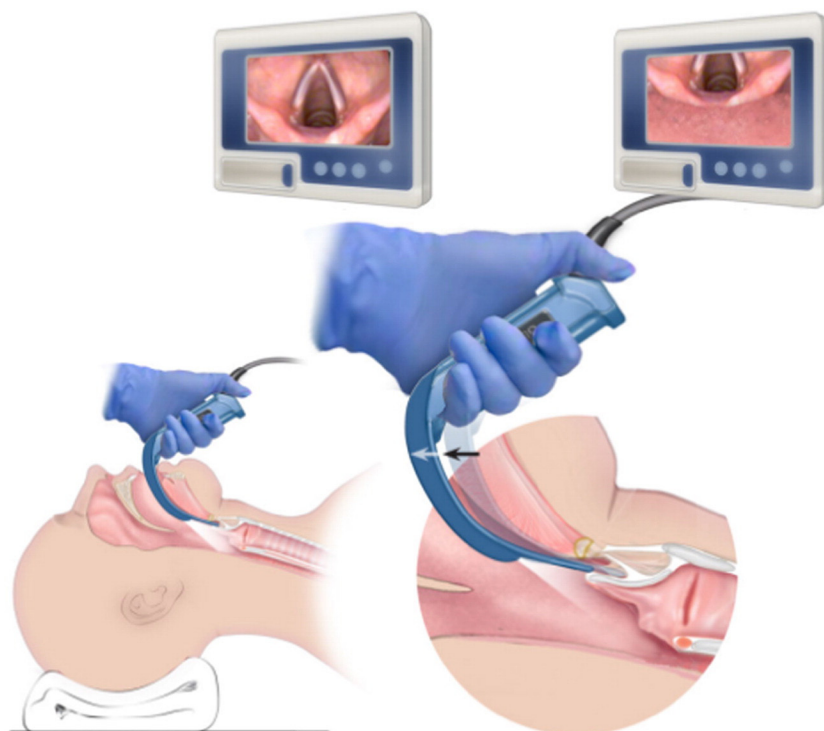
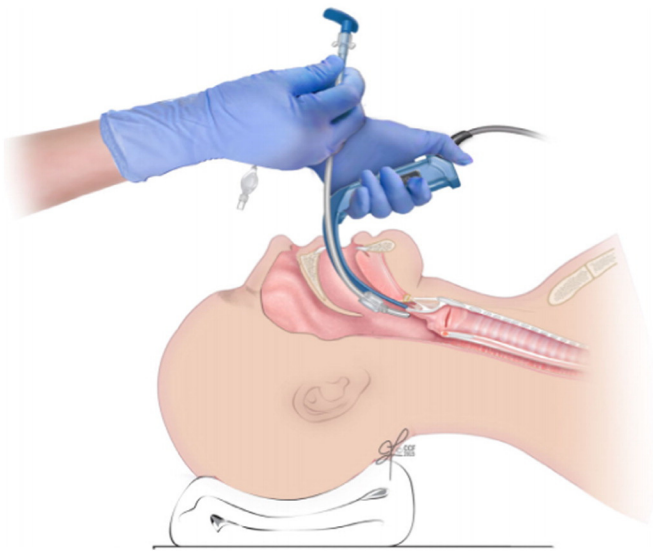


Fig. 3. How the glottic exposure changes with pullback or retraction of the video laryngoscope. Too close a view might not be the best view for intubation.

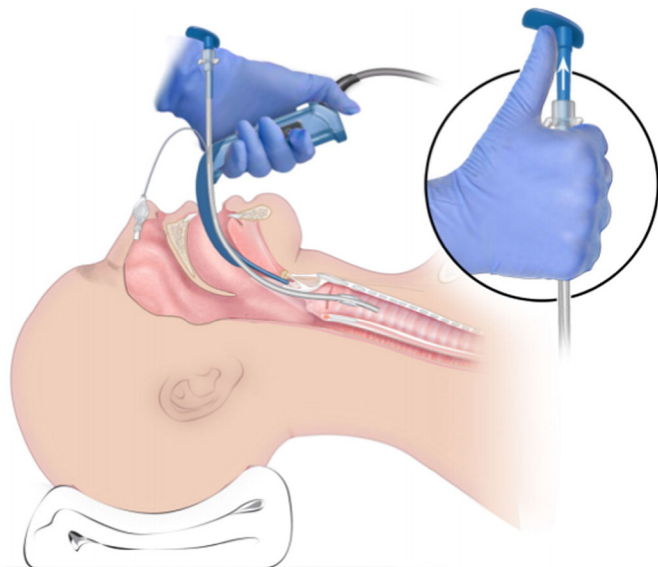


**Fig. 4.** Suggested proximal hand placement on the ET tube to maximize fine motor control. The proximal end is used to pivot the distal tip toward the glottic opening.

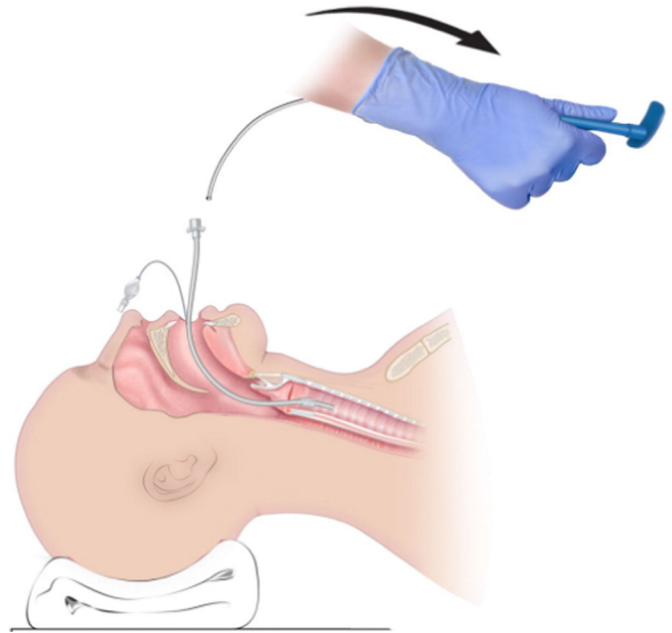
such as rotating the tube or moving anteriorly or posteriorly are amplified in the pharynx, giving the operator more mobility. This substantially improves fine motor control and is often enough to achieve easy passage of the tube through the vocal cords (Fig. 4).

**4.5. Tip 5.** If you encounter difficulty passing the ET tube through the cords, withdraw the stylet 3 to 5 cm to straighten the tip of the tube and then advance it in the right direction

It is not uncommon for users to achieve an excellent view of the glottis when the tip is right at the glottic opening but then experience difficulty advancing the ET tube forward into the glottic aperture. If this happens, the operator can withdraw the stylet 3 to 5 cm with his or her thumb (or ask an assistant to withdraw the stylet slowly) to straighten the tip of the tube just enough to allow forward motion through the vocal cords (Fig. 5). The hyperangulation of the GlideScope's blade and stylet changes the shape of the ET tube distally, interfering with its passage through the cords into the glottic aperture.



**Fig. 5.** Use of the thumb to extract the stylet 3 to 5 cm to facilitate passage through the vocal cords. The stylet is pulled out toward the feet.



**Fig. 6.** Optimal course over which to direct the stylet for gentle removal.

When this difficulty occurs, withdrawing the stylet 3 to 5 cm tends to straighten the tip of the tube and propel it in the right direction. Holding the tube at the proximal end (far from the mouth) allows you to guide the tip toward the vocal cords and to retract the stylet with your thumb (Fig. 5). Once the ET tube is through the cords, the stylet can be removed by pulling it out and down toward the patient's chest and feet, following the shape of the stylet and allowing gentle, atraumatic intubation (Fig. 6).

## 5. Conclusions

Video laryngoscopy offers many advantages in certain situations. Whether for an anticipated difficult airway, for patients with trauma in cervical spine precautions, to facilitate teaching, or simply personal preference, VL can be an invaluable tool in the emergency department. Its technique is similar to the standard DL approach, but subtle differences in the devices can make VL seem difficult to those who do not use it on a regular basis. Direct laryngoscopy is far from obsolete in the world of emergency airway management, but clinicians should have reasonable comfort and experience with all the tools at our disposal so that we can provide the safest possible care for our patients. Typically, practitioners run into 3 problems when using a hyperangulated VL blade: (1) they have the laryngoscope too close to the glottic opening, (2) they cannot guide the tip toward the vocal cords, or (3) they are unable to advance the tip through the cords. We hope that the troubleshooting techniques presented in this article will increase practitioners' comfort and success with the GlideScope video laryngoscope.

## References

- [1] Doyle DJ. A brief history of clinical airway management. *Anesthesiol News* 2008; 9–14.
- [2] Levitan R. Video laryngoscopy, regardless of blade shape, still requires a backup plan. *Ann Emerg Med* 2013;61(4):421–2.
- [3] Harrison D. Benjamin Guy and his mirror. *J Laryngol Otol* 1998;112(3):235–42.
- [4] Carlson JN, Brown CA. Does the use of video laryngoscopy improve intubation outcomes? *Ann Emerg Med* 2014;64(2):165–6.
- [5] Sakles JC, Mosier JM, Chiu S, Keim SM. Tracheal intubation in the emergency department: a comparison of GlideScope® video laryngoscopy to direct laryngoscopy in 822 intubations. *J Emerg Med* 2012;42:400–5.
- [6] Lakticova V, Koenig SJ, Narasimhan M, Mayo PH. Video laryngoscopy is associated with increased first pass success and decreased rate of esophageal intubations

- during urgent endotracheal intubation in a medical intensive care unit when compared to direct laryngoscopy. *J Intensive Care Med* 2013;30:44–8.
- [7] Griesdale DE, Liu D, McKinney J, Choi PT. Glidescope® video-laryngoscopy versus direct laryngoscopy for endotracheal intubation: a systematic review and meta-analysis. *Can J Anaesth* 2012;59(1):41–52.
- [8] Mihai R, Blair E, Kay H, Cook TM. A quantitative review and meta-analysis of performance of non-standard laryngoscopes and rigid fibreoptic intubation aids. *Anaesthesia* 2008;63(7):745–60.
- [9] Cooper RM, Pacey JA, Bishop MJ, McCluskey SA. Early clinical experience with a new videolaryngoscope (GlideScope) in 728 patients. *Can J Anaesth* 2005;52(2):191–8.
- [10] Aziz M. Video laryngoscopy. *Anesthesiol Clin* 2013;31(1):157–66.
- [11] Karalapillai D, Darvall J, Mandeville J, Ellard L, Graham J, Weinberg L. A review of video laryngoscopes relevant to the intensive care unit. *Indian J Crit Care Med* 2014;18(7):442–52.
- [12] Malik MA, Maharaj CH, Harte BH, Laffey JG. Comparison of Macintosh, Truview EVO2, Glidescope, and Airwayscope laryngoscope use in patients with cervical spine immobilization. *Br J Anaesth* 2008;101:723–30.
- [13] Lim Y, Yeo SW. A comparison of the GlideScope with the Macintosh laryngoscope for tracheal intubation in patients with simulated difficult airway. *Anaesth Intensive Care* 2005;33:243–7.
- [14] Jones PM, Turkstra TP, Armstrong KP, Armstrong PM, Cherry RA, Hoogstra J, et al. Effect of stylet angulation and endotracheal tube camber on time to intubation with the GlideScope®. *Can J Anaesth* 2007;54:21–7.
- [15] Turkstra TP, Harle CC, Armstrong KP, Armstrong PM, Cherry RA, Hoogstra J, et al. The GlideScope®-specific rigid stylet and standard malleable stylet are equally effective for GlideScope® use. *Can J Anaesth* 2007;54:891–6.
- [16] Moiser J, Chiu S, Patanwala AE, Sakles JC. A comparison of the GlideScope video laryngoscope to the C-MAC video laryngoscope for intubation in the emergency department. *Ann Emerg Med* 2013;61(4):414–20.
- [17] Kramer DC, Osborn IP. More maneuvers to facilitate tracheal intubation with the GlideScope®. *Can J Anaesth* 2006;53(7):737.
- [18] Cho JE, Kil HK. A maneuver to facilitate endotracheal intubation using the GlideScope. *Can J Anaesth* 2008;55:56–7.
- [19] Neustein SM. Advancing the endotracheal tube smoothly when using the GlideScope®. *Can J Anaesth* 2008;55:314.