

## ORIGINAL CONTRIBUTION

# The Inaccuracy of Using Landmark Techniques for Cricothyroid Membrane Identification: A Comparison of Three Techniques

Aaron E. Bair, MD, MS, and Rupinder Chima, MD

## Abstract

**Objectives:** Successful cricothyrotomy is predicated on accurate identification of the cricothyroid membrane (CTM) by palpation of superficial anatomy. However, recent research has indicated that accuracy of the identification of the CTM can be as low as 30%, even in the hands of skilled providers. To date, there are very little data to suggest how to best identify this critical landmark. The objective was to compare three different methods of identifying the CTM.

**Methods:** A convenience sample of patients and physician volunteers who met inclusion criteria was consented. The patients were assessed by physician volunteers who were randomized to one of three methods for identifying the CTM (general palpation of landmarks vs. an approximation based on four finger widths vs. an estimation based on overlying skin creases of the neck). Volunteers would then mark the skin with an invisible but florescent pen. A single expert evaluator used ultrasound to identify the superior and inferior borders of the CTM. The variably colored florescent marks were then visualized with ultraviolet light and the accuracy of the various methods was recorded as the primary outcome. Additionally, the time it took to perform each technique was measured. Descriptive statistics and report 95% confidence intervals (CIs) are reported.

**Results:** Fifty adult patients were enrolled, 52% were female, and mean body mass index was 28 kg/m<sup>2</sup> (95% CI = 26 to 29 kg/m<sup>2</sup>). The general palpation method was successful 62% of the time (95% CI = 48% to 76%) and took an average of 14 seconds to perform (range = 5 to 45 seconds). In contrast, the four-finger technique was successful 46% of the time (95% CI = 32% to 60%) and took an average of 12 seconds to perform (range = 6 to 40 seconds). Finally, the neck crease method was successful 50% of the time (95% CI = 36% to 64%) and took an average of 11 seconds to perform (range = 5 to 15 seconds).

**Conclusions:** All three methods performed poorly overall. All three techniques might potentially be even less accurate in instances where the superficial anatomy is not palpable due to body habitus. These findings should alert clinicians to the significant risk of a misplaced cricothyrotomy and highlight the critical need for future research.

ACADEMIC EMERGENCY MEDICINE 2015;22:000-000 © 2015 by the Society for Academic Emergency Medicine

Successful cricothyrotomy is predicated on accurate identification of the cricothyroid membrane (CTM) by palpation of superficial anatomy.<sup>1,2</sup> This is particularly relevant to techniques like the rapid four-step technique, where the skin and CTM can be incised simultaneously, thus saving critical time.<sup>3-5</sup> However, a misplaced incision, particularly if too high in the neck, can lead to serious complications.<sup>2</sup> A misplaced incision puts surrounding vascular structures at

risk,<sup>6,7</sup> can prolong time to completion, and can lead to hypoxia or death.

In contrast to the rapid four-step technique, one approach to cricothyrotomy relies on making a midline vertical incision to more directly identify the CTM. Such identification is still often based on palpation of the membrane through the incision, as the inevitable bleeding frequently obscures direct visualization of the membrane. Regardless of technique employed, various

From the Department of Emergency Medicine, University of California, Davis Health System, Sacramento, CA.

Received December 2, 2014; revision received March 2, 2015; accepted March 31, 2015.

Presented at the Society for Academic Emergency Medicine Annual Meeting, Dallas, TX, May 2014.

The authors have no relevant financial information or potential conflicts to disclose.

Supervising Editor: Robert F. Reardon, MD.

Address for correspondence and reprints: Aaron E. Bair, MD, MS; e-mail: aebair@ucdavis.

sources and authoritative texts that discuss invasive airway techniques start with the presumption that the relevant anatomy is readily identifiable.<sup>8,9</sup> However, recent research has indicated that the accuracy of identification of the CTM can be as low as 30%, even in the hands of skilled providers.<sup>10–12</sup>

To date, there are very little data to suggest how to best identify the CTM preoperatively. General educational approaches stress palpation of the thyroid cartilage as a key landmark. Occasionally other “best-guess” options, such as using four finger breadths (patient’s sized) to estimate the CTM location relative to the sternal notch, have been promoted.<sup>9</sup> More recently, an additional technique has been suggested that is based on overlying skin creases.<sup>13</sup>

We sought to compare these three different methods of identifying the CTM and assess their individual overall accuracy, as well as other features relevant to the very time-sensitive procedure of cricothyrotomy.

## METHODS

### Study Design

This was a prospective randomized trial using multiple emergency physician (EP) assessors each employing a randomly assigned technique on an individual patient selected from a convenience sample of patients waiting for care in the emergency department (ED). The study took place from June to November 2013. The institutional human subjects committee approved this study.

### Study Setting and Population

Patients recruited to be palpated were termed study “subjects,” whereas physician participants who were recruited to identify the CTM were termed “assessors.” Both groups, subjects and assessors, were consented for participation in this study. After providing written informed consent, each subject was assessed by three different EP assessors who were randomized to one of three methods for identifying the CTM: general palpation of landmarks versus an approximation based on four finger widths versus an estimation based on overlying neck creases.

Patients were identified in the ED of a busy academic Level I trauma center. The patients were otherwise awaiting further evaluation and had sufficient waiting time to complete consent forms and enrollment. Subjects were excluded if they were unable to lay supine, were undergoing evaluation for cervical spine injury, had prior neck surgery or radiation, or were younger than 18 years old.

### Study Protocol

**Sample Size Determination.** Given recent research suggesting an accuracy as low as 30%, we estimated that a more acceptable lower range would be 60%. We attempted to power our study to detect a 30% absolute difference between techniques (90% power, alpha 0.05) with an estimated required sample size of 44 subjects.

**Selection of Physician Assessors.** Emergency physician assessors were eligible to participate if they had been formally trained in surgical airway techniques. For

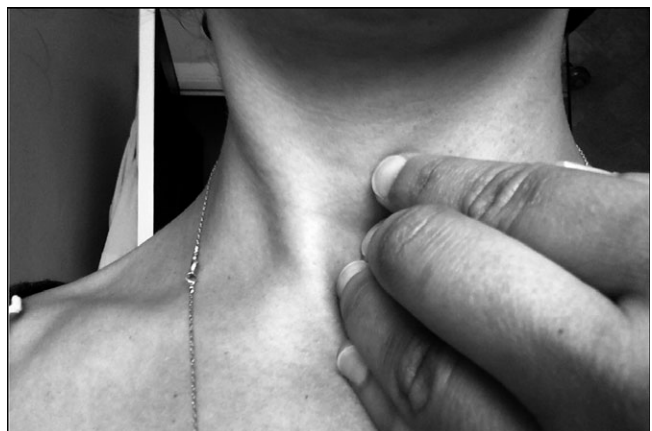
the residents at our institution this involves a formalized airway curriculum and included cadaver-based training with multiple invasive techniques for each of the residents. The physicians were approached to participate if they were available in the ED at the time enrollment was occurring. First-year emergency medicine residents did not participate. Assessors could participate in the enrollment of multiple subjects but could only assess each individual subject once. Each subject was evaluated by three different physician assessors.

**Data Collection.** After patient enrollment, a sealed opaque envelope containing a randomly assigned order of techniques was unsealed for each participating physician assessor. The assessor was then given a standardized introduction to marking the membrane, as well as a standardized overview of the technique that he or she was to employ to identify the CTM. This overview consisted of slides showing images, landmarks, and key details relative to the technique.

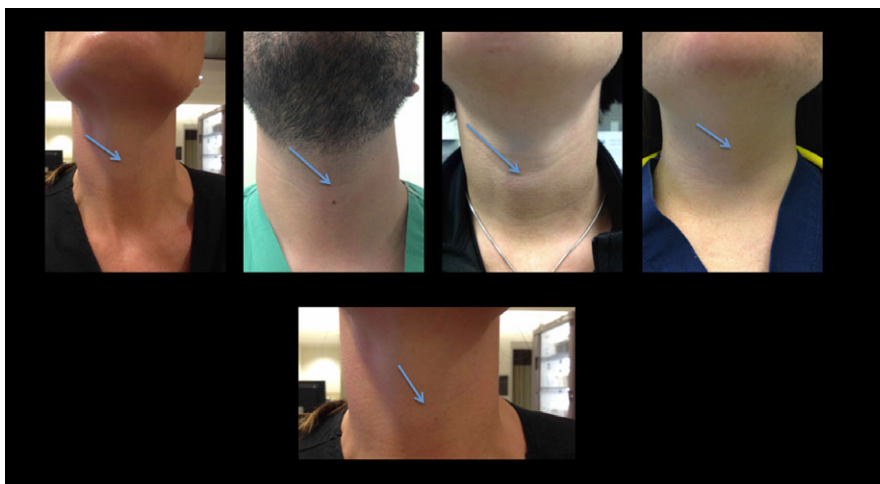For the general palpation technique, the assessor was instructed to find the CTM using either the thyroid notch or sternal notch as a starting point. As both approaches (i.e., top-down or bottom-up) are commonly used, we did not mandate an approach. However, the particular approach used was tracked.

For the four-finger technique, the assessor was asked to place his or her small finger in the sternal notch with the tip of the index finger estimating the CTM. Assessors were asked to be aware of relative body size differences between assessor and subject. Large differences in size would require a relative adjustment in the assessment. Figure 1 demonstrates hand position for the four-finger technique.

For the neck crease technique, the assessor was asked to identify the horizontal anterior neck crease on the subject. The assessor was then asked to estimate which crease may overlie the CTM. In the case of multiple creases, it was left to assessor judgment as to which crease to select based on observed (nonpalpated) anatomy and relative position in the neck. Figure 2 shows anterior neck creases commonly present in adults.



**Figure 1.** Demonstration of the four-finger technique. The small finger is placed in the sternal notch with the tip of the index finger estimating the cricothyroid membrane.



**Figure 2.** Anterior neck creases.

According to our protocol, the physician assessor would then mark the skin with a fluorescent pen. The pen would leave an invisible mark that could subsequently be identified using ultraviolet light. The assessors used variable colored pens so that their marks could be easily identified and distinguished from other assessors' marks. However, as they were not visible with regular light, inter-rater bias was minimized (see Figure 3 as an example of the multiple fluorescent colored markings). These markings were then covered by a simple clear dressing so that subsequent use of ultrasound gel would not smear or obliterate the markings.

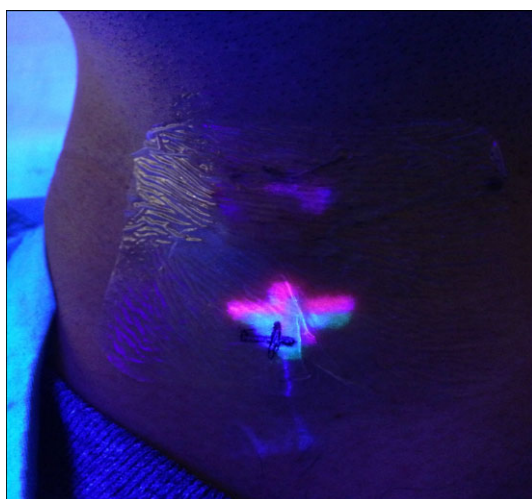
At each phase of assessment our subjects were placed in a consistent neutral position to minimize relative movement of superficial anatomy and skin relative to underlying landmarks. Likewise, this would reasonably replicate positioning in the context of cervical spine immobilization (i.e., trauma).

We used ultrasound as our criterion standard for localization of the CTM. A single expert evaluator used

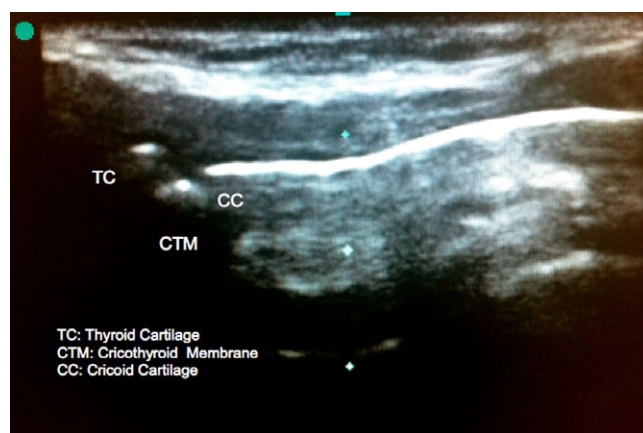
ultrasound to identify the borders of the CTM in all subjects in this study. Additionally, this single evaluator recorded all technique and body habitus-related details. Prior to the initiation of the study, the ultrasound evaluator underwent focused training by local experts specifically with the intent of refining the protocol. This pretrial assessment of the ultrasound technique relied on direct neck dissection in 12 adult human cadavers to correlate CTM location with ultrasound findings. Figure 3–5 demonstrate the fundamental portions of the ultrasound technique used.

#### Outcome Measures

Our primary outcome was success or failure to place an “X” mark on the skin overlying the CTM. The placement was considered correct if cross point of the “X” was between the superior and inferior borders of the CTM and within 0.5 cm of midline. Our secondary outcome was the time it took to perform the assessment. We measured from the time when the assessor initially touched or, in the case of the crease method, began

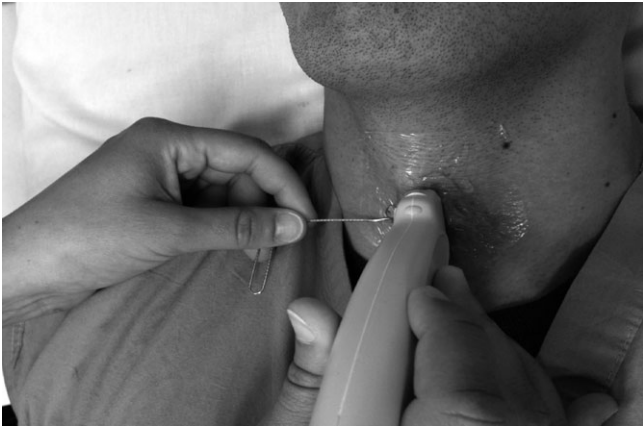

**Figure 3.** An example of the use of multiple fluorescent markings used to distinguish location estimation by multiple assessors.



**Figure 4.** This ultrasound image demonstrates a midline, long-axis view of the anterior neck at the level of the thyroid cartilage and cricothyroid membrane (CTM). The gap between the thyroid cartilage (TC) and the cricoid cartilage (CC) is the CTM.





**Figure 5.** The interposition of an echodense object (i.e., paperclip) was used to cast a shadow at the level of the cricothyroid membrane border, which was then used to align and mark the corresponding position on the skin.

visual inspection, to the time the pen was placed on the skin.

### Data Analysis

We performed all statistical analyses using STATA software version 12. We report descriptive analysis with means, ranges, and 95% confidence intervals (CI).

## RESULTS

Table 1 displays basic demographics of both the patient subjects and the physician assessors. We enrolled 50 adult patients, with an approximately even sex distribution. Our average patient was overweight with a BMI of 28 kg/m<sup>2</sup>, and 34% were obese (BMI > 30). Table 2 summarizes our primary and secondary outcomes. Figures 6 and 7 demonstrate the individual assessments based on technique and sex, respectively. The general palpation method was successful 62% (95% CI = 48% to 76%) of the time and took an average of 14 seconds (range = 5 to 45 seconds) to perform. Ninety percent of the time the technique was performed in a “top-down” direction, using the thyroid cartilage as a key landmark. In contrast, the four-finger technique was successful 46% (95% CI = 32% to 60%) of the time and took an average of 14 seconds (range = 5 to 45 seconds) to perform. Finally, the neck crease method was successful

**Table 1**  
Demographics of Patient Subjects and Physician Assessors

Demographic	
Total enrolled	50
Sex, female, %	52%
Neck circumference (mean), cm	40 (39–42)
Body mass index (mean), kg/m <sup>2</sup>	28 (26–29)
% obese (BMI > 30)	34% (17/50)
CTM height (mean), cm	0.97 (0.92–1.0)
Assessor demographics (N = 49)	
Attending or fellow	23
PGY3	12
PGY2	14

**Table 2**  
Success by Technique Type

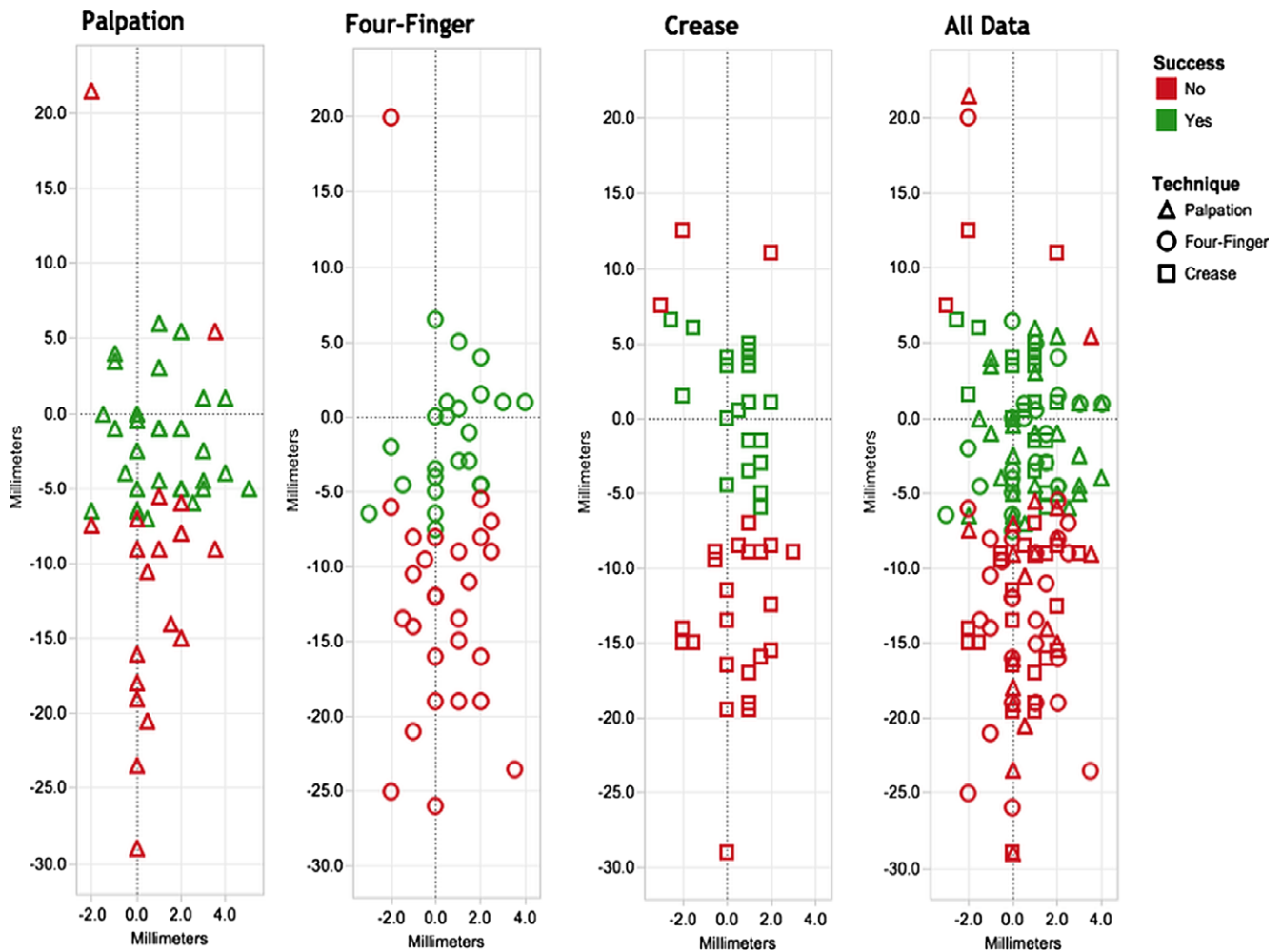
	Palpation	Four Finger	Neck Crease
% Correct identification	62% (48–76)	46% (32–60)	50% (36–64)
Time to mark (seconds)	14 (12–16), Range = 5–45	12 (10–13), Range = 6–40	11 (10–12), Range = 5–15
No. too high	2	1	3
(95% CI), N = 50.			

50% (95% CI = 36% to 64%) of the time and took an average of 11 seconds (range = 5 to 15 seconds) to perform. Additionally, we recorded the number of anterior neck creases to estimate the prevalence of patients with multiple creases. We found that 70% (35 of 50) of our population had two creases. Only two patients had no observable crease, six had one crease, and seven patients had greater than two. In the two-crease group, when the CTM was correctly identified (n = 18), there was an essentially even split between the superior crease (10 of 18) versus the inferior crease (eight of 18). For all techniques we report the individual incidences of when an assessment was above the CTM, as we assumed that it would be worse for an incision to be too high rather than too low (i.e., tracheostomy).

## DISCUSSION

Despite significant advances in emergency airway management, including various techniques (e.g., rapid sequence intubation), videolaryngoscopy, and the adoption of various rescue adjuncts (e.g., laryngeal mask airways), cricothyrotomy is still an important technique.<sup>14,15</sup> The technique is frequently taught, but infrequently employed in actual clinical practice with current estimates approximating 1%. The incidence is likely much lower in community practice. For the procedure to be effective, time is of the essence, and rapid and correct identification of the CTM can limit unnecessary steps and save crucial time and limit hypoxic injury.

Educational resources that discuss the various techniques of emergency cricothyrotomy often begin with the assumption that the pertinent landmarks are quickly and accurately identifiable. However, recent reports from the anesthesiology literature suggest that this might not be an accurate assumption.<sup>10–12,16</sup> The magnitude of the problem, while not frequent in occurrence, can be devastating for the individual patient. Injury to adjacent structures, as well as prolonged duration of the procedure, can lead to hypoxic injury and death.<sup>2,5–7,17</sup> There is little prior literature to help inform best teaching practices. Our study contributes to the evolving literature that suggests that CTM localization is fraught with error. As such, unless one is confident of the CTM location based on clear anatomic landmarks, the current evidence appears to support initiating a cricothyrotomy with a midline incision to better appreciate the key anatomic structures.



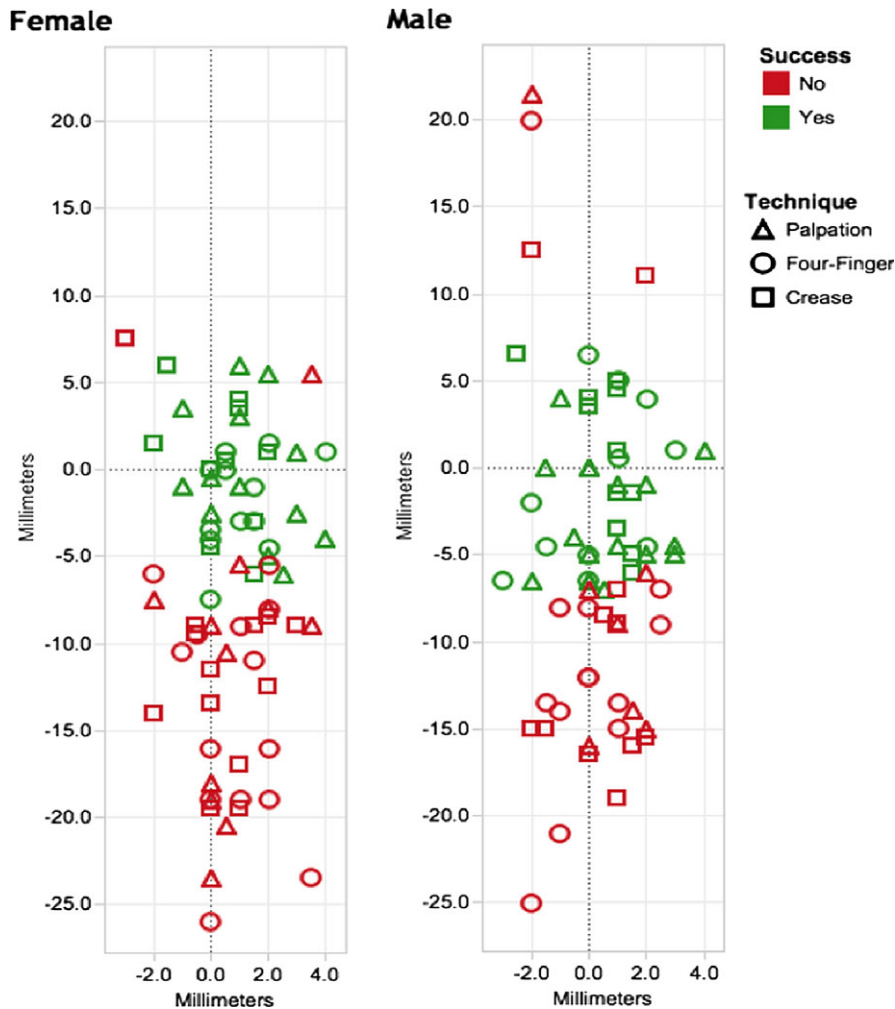
**Figure 6.** Distances from cricothyroid membrane (CTM) center of individual assessments by technique. Green color signifies successful placement over (CTM).

In addition to accuracy, we tracked time as a secondary outcome. Our intention was to document extremes of time (inordinately slow or fast). Our findings, regardless of ultimate accuracy, reflect the nature of the technique. For example, one might surmise that quickly examining a subject's neck and observing a single lateral crease might take a second, whereas a more hands-on approach would be expected to take longer. If it were to be shown that there was comparable accuracy to other techniques, the faster technique might fairly be promoted as a time saver. Our results, however, did not reveal compelling findings with respect to time.

While we used ultrasound in our study as our criterion standard, we would urge caution when using it in an unanticipated failed airway scenario. Prior studies have shown that it can be accurate and, once the unit is prepared, the time to image acquisition may be short.<sup>18-21</sup> Prior preparation of the machine with premarking of the anatomic structures may make the use of ultrasound more practical.<sup>19</sup> However, in the emergent unanticipated failed airway situation, it is likely to contribute to significant delay given the logistics of preparing the ultrasound unit.

Our study suggests that all three of the techniques performed poorly and that none of these techniques significantly outperformed the others. We propose that training approaches should take into account that CTM localization cannot be assumed to be readily identifiable. For example, much of the training for emergency cricothyrotomy involves manikin-based training. However, this often isolates the technical elements of the procedure and takes for granted the proper identification of the CTM. This may be due, in part, to the fact that many simulator products have very low fidelity with respect to anterior neck anatomy. In the absence of improved simulator models, trainings will need to account for this deficiency (e.g., use of appropriate animal or cadaver experience).

Our study highlights an important clinical problem and provides further evidence for the need to develop reliable methods for CTM identification. The significant risk of a misplaced cricothyrotomy was reported more than 30 years ago, but a solution to this problem has not been established.<sup>19,21,22</sup> The authors of several previous reports believe that the best way to identify the CTM is to palpate the sternal notch, the hyoid bone, the thyroid cartilage, as well as the cricoid cartilage



**Figure 7.** Distances from cricothyroid membrane (CTM) center for all assessment techniques by sex. Green color signifies successful placement over CTM.

(personal communication with Drs. Clinton and McGill, e-mail, April 2015). They also recommend making an initial midline incision with identification of the CTM by palpation through the incision. However, these recommendations have not been studied nor published.

### LIMITATIONS

Our assessors were a mixed group of emergency medicine residents and faculty. Our expectation is that this group of individuals is sufficiently representative because any of these providers could be called upon to perform a cricothyrotomy in their current clinical roles. As such, we propose that this represents a reasonable group of assessors despite some heterogeneity. However, we certainly acknowledge that our results might be different among a group of more experienced physicians.

While we recognize that hyperextension of the neck can widen the CTM and make identification more successful,<sup>16</sup> we opted to maintain our subjects in a neutral cervical spine position. Our intention was to maintain consistent positioning throughout the assessment process, therefore limiting subject variability. Additionally,

this would reasonably replicate positioning in the setting of a traumatically injured patient requiring spine immobilization.

This study was performed under optimal circumstances in a nonrushed, non-time-critical setting. Cricothyrotomy for failed airway management is generally done in haste and is potentially fraught with anxiety and error. As such, we expect that the accuracy reported in this study is actually overestimated. However, this framework for assessment serves as a general baseline for further comparisons.

### CONCLUSIONS

All three methods performed poorly overall without a technique demonstrating clear superiority. We further speculate that all of these techniques could be less accurate in instances where the superficial anatomy is not palpable due to body habitus or when done in haste in real clinical circumstances. Our findings agree with previous reports suggesting that identification of the cricothyroid membrane is more difficult than expected. This should alert clinicians to the significant risk of a misplaced cricothyrotomy and highlight the critical need for future research.

## References

1. Mace SE. Cricothyrotomy. *J Emerg Med* 1988;6:309–19.
2. McGill J, Clinton JE, Ruiz E. Cricothyrotomy in the emergency department. *Ann Emerg Med* 1982;11:361–4.
3. Brofeldt BT, Panacek EA, Richards JR. An easy cricothyrotomy approach: the rapid four-step technique. *Acad Emerg Med* 1996;3:1060–3.
4. Holmes JF, Panacek EA, Sakles JC, Brofeldt BT. Comparison of 2 cricothyrotomy techniques: standard method versus rapid 4-step technique. *Ann Emerg Med* 1998;32:442–6.
5. Bair AE, Panacek EA, Wisner DH, Bales R, Sakles JC. Cricothyrotomy: a 5-year experience at one institution. *J Emerg Med* 2003;24:151–6.
6. Salah N, El Saigh I, Hayes N, McCaul C. Airway injury during emergency transcutaneous airway access: a comparison at cricothyroid and tracheal sites. *Anesth Analg* 2009;109:1901–7.
7. Little CM, Parker MG, Tarnopolsky R. The incidence of vasculature at risk during cricothyroidostomy. *Ann Emerg Med* 1986;15:805–7.
8. Herbert RB, Bose S, Mace SE. Cricothyrotomy and percutaneous translaryngeal ventilation. In: Roberts J, ed. *Roberts and Hedges' Clinical Procedures in Emergency Medicine*, 6th ed. Philadelphia, PA: Saunders, 2013.
9. Vissers RJ, Bair AE. Surgical Airway Management. In: Walls RM, Murphy MF (editors). *Manual of Emergency Airway Management*. 4th ed. Philadelphia, PA: Lippincott, Williams and Wilkins, 2012 pp 193–219.
10. Elliott DS, Baker PA, Scott MR, Birch CW, Thompson JM. Accuracy of surface landmark identification for cannula cricothyroidotomy. *Anaesthesia* 2010;65:889–94.
11. Eisenburger P, Laczika K, List M, et al. Comparison of conventional surgical versus Seldinger technique emergency cricothyrotomy performed by inexperienced clinicians. *Anesthesiology* 2000;92:687–90.
12. Lamb A, Zhang J, Hung O, et al. Accuracy of identifying the cricothyroid membrane by anesthesia trainees and staff in a Canadian institution. *Can J Anaesth* 2015;62:495–503.
13. Kwofie K, Hung O, Hung C, Hung D. The use of neck surface landmarks (Launcelott Creases) to locate the cricoid artilage [abstract]. *Anesthesiology* 2008;109:176.
14. Bair AE, Filbin MR, Kulkarni RG, Walls RM. The failed intubation attempt in the emergency department: analysis of prevalence, rescue techniques, and personnel. *J Emerg Med* 2002;23:131–40.
15. Sakles JC, Laurin EG, Rantapaa AA, Panacek EA. Airway management in the emergency department: a one-year study of 610 tracheal intubations. *Ann Emerg Med* 1998;31:325–32.
16. Aslani A, Ng SC, Hurley M, McCarthy KF, McNicholas M, McCaul CL. Accuracy of identification of the cricothyroid membrane in female subjects using palpation: an observational study. *Anesth Analg* 2012;114:987–92.
17. Mabry RL. An analysis of battlefield cricothyrotomy in Iraq and Afghanistan. *J Spec Operations Med* 2012;12:17–23.
18. Nicholls SE, Sweeney TW, Ferre RM, Strout TD. Bedside sonography by emergency physicians for the rapid identification of landmarks relevant to cricothyrotomy. *Am J Emerg Med* 2008;26:852–6.
19. Mallin M, Curtis K, Dawson M, Ockerse P, Ahern M. Accuracy of ultrasound-guided marking of the cricothyroid membrane before simulated failed intubation. *Am J Emerg Med* 2014;32:61–3.
20. Teoh WH, Kristensen MS. Ultrasonographic identification of the cricothyroid membrane. *Anaesthesia* 2014;69:649–50.
21. Curtis K, Ahern M, Dawson M, Mallin M. Ultrasound-guided, Bougie-assisted cricothyroidotomy: a description of a novel technique in cadaveric models. *Acad Emerg Med* 2012;19:876–9.
22. Erlandson MJ, Clinton JE, Ruiz E, Cohen J. Cricothyrotomy in the emergency department revisited. *J Emerg Med* 1989;7:115–8.