

# Airway Anesthesia

## Theory and Practice



D. John Doyle, MD, PhD<sup>a,b,\*</sup>

### KEYWORDS

- Airway anesthesia • Airway blocks • Awake intubation • Benzocaine toxicity
- Fiber optic intubation • Lidocaine toxicity • Local anesthesia • Topical anesthesia

### KEY POINTS

- Lidocaine is available as a regular solution, a viscous solution, a gel, an ointment, or in a spray can.
- Topicalization is the easiest method for anesthetizing the airway; just spray lidocaine directly onto airway mucosa.
- Needle-based airway blocks are more complicated than noninvasive methods of providing anesthesia to the airway and are usually unnecessary to achieve good airway anesthesia.
- Benzocaine topical anesthesia, although highly effective, is sometimes complicated by methemoglobinemia, the presence of elevated methemoglobin levels within circulating erythrocytes.
- Local anesthetic toxicity with lidocaine, the most commonly used drug for airway anesthesia, can range from tingling, perioral numbness, and paraesthesias to convulsions, coma, and complete cardiorespiratory collapse.

### INTRODUCTION

Awake tracheal intubation is commonly used when ordinary intubation (for example, attempting direct laryngoscopy after the induction of general anesthesia) is expected to be difficult or hazardous.<sup>1–8</sup> Possible examples include patients with large glottic tumors, patients with unstable cervical spines, patients known to be difficult to intubate by virtue of previous anesthetic misadventures, and numerous other conditions.<sup>9–15</sup>

---

This is an updated, reorganized and expanded version of an earlier article published in the 7th Annual Anesthesiology News Guide to Airway Management. August 2014. Available online at: [http://anesthesiologynews.com/download/Topicals\\_ANGAM14\\_WM.pdf](http://anesthesiologynews.com/download/Topicals_ANGAM14_WM.pdf).

<sup>a</sup> Department of General Anesthesiology, Cleveland Clinic Foundation, Abu Dhabi, UAE;

<sup>b</sup> Department of General Anesthesiology, Anesthesiology Institute, Cleveland Clinic Abu Dhabi, PO Box 112412, Abu Dhabi, UAE

\* Department of General Anesthesiology, Anesthesiology Institute, Cleveland Clinic Abu Dhabi, PO Box 112412, Abu Dhabi, UAE.

*E-mail address:* [djdoyle@hotmail.com](mailto:djdoyle@hotmail.com)

Anesthesiology Clin 33 (2015) 291–304

<http://dx.doi.org/10.1016/j.anclin.2015.02.013>

[anesthesiology.theclinics.com](http://anesthesiology.theclinics.com)

1932-2275/15/\$ – see front matter © 2015 Elsevier Inc. All rights reserved.

Regardless of the reason that awake intubation is warranted, however, several underlying principles hold. First, although sedation using drugs such as midazolam, fentanyl, propofol, remifentanyl, and dexmedetomidine are undoubtedly useful adjuncts to performing an awake intubation, the “secret recipe” is undoubtedly in obtaining complete anesthesia to the airway structures. With good airway anesthesia, minimal or even no sedation at all can be used, and patient cooperation is much easier to achieve. The purpose of this article is to help make this happen.

## MOLECULAR MECHANISMS OF ANESTHESIA

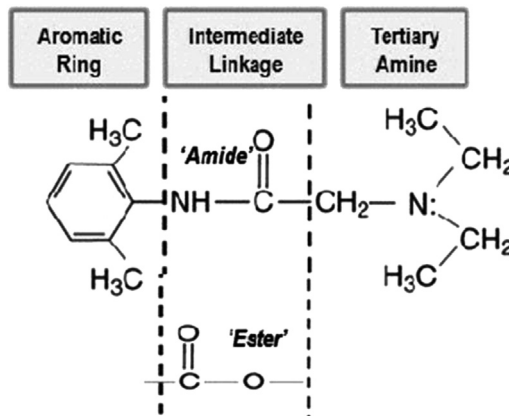
The mechanism by which local anesthetics work has long interested clinicians, and it is customary to comment on this matter in all articles dealing with local anesthesia. Key to this matter is the molecular arrangement common to all local anesthetics (Fig. 1).

Until recently, the conventional wisdom is that local anesthetics block voltage-gated sodium channels by binding to a site in the lumen of that channel, thus preventing the flow of current.<sup>16</sup> However, this model has been challenged recently based on the finding that some local anesthetic molecules are too small to fully occlude the sodium channel. This finding has led to an alternative hypothesis that local anesthetics prevent current flow through sodium channels by introducing a positive charge that electrostatically impedes the flow of sodium ions, rather than acting by physical means. For more details, the interested reader is referred to an article by Scheuer.<sup>17</sup>

Fortunately for clinicians, local anesthetics work regardless of how well we understand the underlying molecular mechanisms.

## SIX KEY AIRWAY MANAGEMENT DECISIONS

The process begins by making 6 key airway management decisions. The first question asks whether the condition of the airway is so bad that the airway is best managed via a tracheostomy carried out under local anesthesia. Assuming that this is not the case, and additionally, assuming that a supraglottic airway is also inappropriate, let us proceed with the assumption that awake tracheal intubation is desired. Under these assumptions, the second question is then whether one should use the oral as opposed to



**Fig. 1.** Most local anesthetics have an aromatic ring on one end, a tertiary amine on the other end, and 1 of 2 forms of an intermediate linkage. This last structural difference (amide vs ester) determines the pathway by which the local anesthetic is metabolized and its potential for allergic reactions. (From Becker DE, Reed KL. Local anesthetics: review of pharmacological considerations. *Anesth Prog* 2012;59(2):90–101; with permission).

the nasal route. In patients with severe trismus, for example, a nasal approach is generally necessary. In addition, the surgeon will sometimes request nasal intubation to make the surgery easier.

The third question is whether one should use needle-based local anesthetic blocks or go with an approach relying entirely on topical anesthesia. Although my preference is for the latter approach, some clinicians favor the use of nerve blocks because of a belief that the chance of local anesthetic toxicity is reduced by virtue of needle-based local anesthetic blocks requiring fewer drugs.

A fourth question is whether glycopyrrolate should be given as an antisialagogue. Although I do this only occasionally, this is a routine practice for a great many clinicians.

The fifth question concerns the appropriate sedation protocol to use. Options include no sedation whatsoever; midazolam, fentanyl, remifentanyl dexmedetomidine and propofol in various doses; and other methods (Table 1). I often give midazolam, 1 mg, fentanyl, 50 µg, and later propofol, 10 to 20 mg, just before the bronchoscope is introduced.

The sixth question concerns the choice of method of tracheal intubation. Options include fiber-optic intubation, video laryngoscopy, or even regular direct laryngoscopy.

## UPPER AIRWAY BLOCKS

For cases in which topical anesthesia is not desired or proven to be ineffective, nerve blocks can be used. Needle blocks are at least relatively contraindicated in patients with coagulopathies or on anticoagulation. Patients should always be aspirated before injecting to help ensure that the needle is not in a blood vessel. Potential complications of these blocks include bleeding, nerve injury, and seizures from intravascular injection.

### *Glossopharyngeal Block*

This block numbs the oropharynx by anesthetizing the glossopharyngeal nerve (ninth cranial nerve), a mixed nerve that provides sensation to the posterior third of the tongue, the vallecula, the anterior surface of the epiglottis (via the lingual branch), the tonsils (via the tonsillar branch), and the pharyngeal walls (via the pharyngeal

**Table 1**  
Commonly used adjunctive medications for awake intubation in adult patients

Medication	Dosage, Route, and Timing	Action	Reversal Agent
Glycopyrrolate	0.2–0.4 mg IV or IM given 15–30 min preprocedure	Antisialagogue	None
Midazolam	0.5–4 mg IV (titrate to effect)	Sedative	Flumazenil
Fentanyl	25–100 µg IV (titrate to effect)	Sedative	Naloxone
Remifentanyl	Loading dose: 0.75 µg/kg Infusion: 0.075 µg/kg/min (Cattano et al, <sup>45</sup> 2012)	Sedative	Naloxone
Dexmedetomidine	Loading dose: 1 µg/kg/h over 10-min Infusion: 0.7 µg/kg/h (from product monograph)	Sedative	None

These are guidelines only; smaller doses may be appropriate in frail patients, and larger doses may be appropriate in some others.

From Doyle J. Topical and regional anesthesia for awake intubation. 7th Annual Anesthesiology News Guide to Airway Management. 2014. Available at: [http://anesthesiologynews.com/download/Topicals\\_ANGAM14\\_WM.pdf](http://anesthesiologynews.com/download/Topicals_ANGAM14_WM.pdf). Accessed March 23, 2014; with permission.

branch). The glossopharyngeal nerve can be blocked by injecting about 5 mL of local anesthetic (eg, 2% lidocaine) submucosally at the caudal aspect of the posterior tonsillar pillar, where it crosses the palatoglossal arch. Alternatively, the block can be achieved using direct mucosal application via pledgets soaked with local anesthetic (see [Fig. 6](#)), or even by spraying topical anesthesia onto the above-mentioned region. Some clinicians prefer to avoid needles for this block because it avoids the possibility of seizures from inadvertent injection into the carotid artery. Finally, although this block facilitates intubation by blocking the gag reflex, it is not adequate as a solo technique.

### ***Superior Laryngeal Block***

This block numbs the larynx above the vocal cords. The internal branch of the superior laryngeal nerve originates from the superior laryngeal nerve lateral to the greater cornu of the hyoid bone and passes approximately 2 to 4 mm inferior to the greater cornu of the hyoid bone where it pierces the thyrohyoid membrane to innervate the tongue base, the posterior surface of the epiglottis, the aryepiglottic folds, and the arytenoids. To perform this block, the patient is placed in a supine position with the head extended. The hyoid bone is identified and a 25-gauge needle advanced until it makes contact with greater cornu of this structure on the side to be blocked. The needle is then walked off the bone inferiorly and advanced 2 to 3 mm. After a negative aspiration test, 2 to 3 mL of local anesthetic is injected, with an additional 1 to 2 mL administered as the needle is withdrawn. This block is not adequate as a solo technique for airway anesthesia. A video showing the technique is available at <http://www.youtube.com/watch?v=8bRIUy7kOLM>.

### ***Translaryngeal Block***

The translaryngeal block numbs the larynx and trachea below the cords by anesthetizing the recurrent laryngeal nerve, which provides sensation to the trachea and vocal cords. To perform this block, a 5-mL syringe filled with 4% lidocaine and fitted with a 22- or 20-gauge intravenous (IV) catheter is advanced through the cricothyroid membrane until air is aspirated into the syringe. The needle is removed, leaving the IV catheter. Then 4 mL of 4% lidocaine is injected, inducing coughing that scatters the local anesthetic. A video showing the technique is available at <http://www.youtube.com/watch?v=I8IF7PjDhnA>.

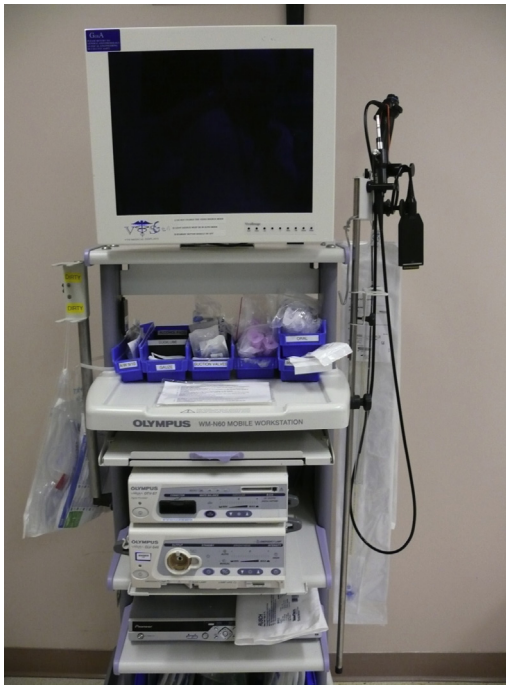## **PROCEDURAL MATTERS: 8 STEPS TO AWAKE INTUBATION**

The procedure to provide anesthesia via awake intubation involves 8 steps. Note that although the discussion here applies to the use of a fiber optic bronchoscope ([Fig. 2](#)), the use of a video laryngoscope ([Fig. 3](#))<sup>18–23</sup> is another possibility.

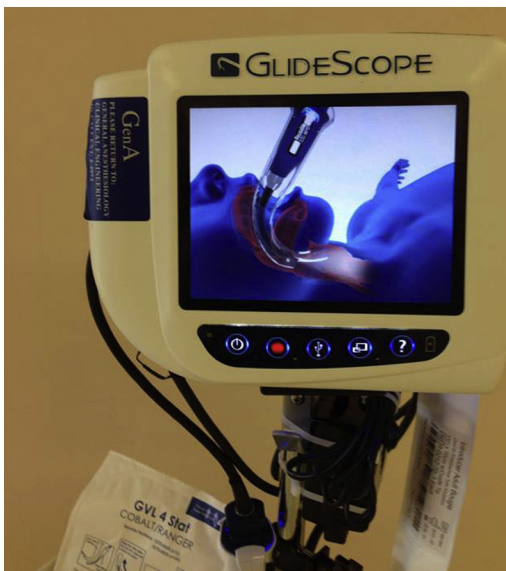The first step in awake intubation is careful preparation: reviewing the clinical issues, checking the equipment, explaining your plan to the patient and clinical team members, applying patient monitors, applying oxygen via nasal cannula, checking the Yan-kauer and bronchoscope suction systems, checking the patient's IV line, possibly administering glycopyrrolate, and administering sedation if warranted.

The next step is to have the patient gargle 2% viscous lidocaine while positioned upright, administered using a small disposable drinking cup ([Fig. 4](#)). An alternative to this step involves the use of lidocaine paste ([Fig. 5](#)). Additionally, some clinicians like to use lidocaine-soaked pledgets as part of the procedure ([Fig. 6](#)).

This is followed by administering 4% lidocaine to oropharyngeal and glottic structures using an oxygen-driven power sprayer ([Fig. 7](#)).



**Fig. 2.** A fiber optic bronchoscope is the most commonly used device for awake intubation. This model provides a video display that is especially valuable for use in teaching. In addition to airway guides and devices to administer local anesthesia, a bag on the left contains 3 sizes of the i-gel supraglottic airway that can be used as a conduit for intubation, while various kinds of airway catheters hang on the right side of the cart.



**Fig. 3.** A video laryngoscope such as the GlideScope (Verathon, Bothell, WA) is sometimes used for awake intubation, for example, when placing special tracheal tubes using a bore too small to admit a bronchoscope.

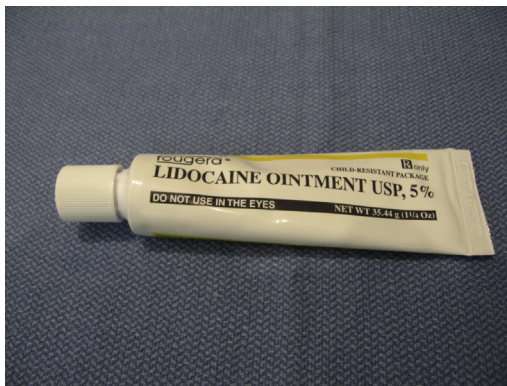

**Fig. 4.** Viscous lidocaine (Roxane Laboratories, Columbus, OH) at 2% can be given using a small disposable drinking cup. It is gargled, then expectorated; most patients prefer to be sitting up rather than supine for this. In addition, letting the patient hold and control the Yankauer sucker to remove any excess anesthetic or to use after they have had enough can be helpful.

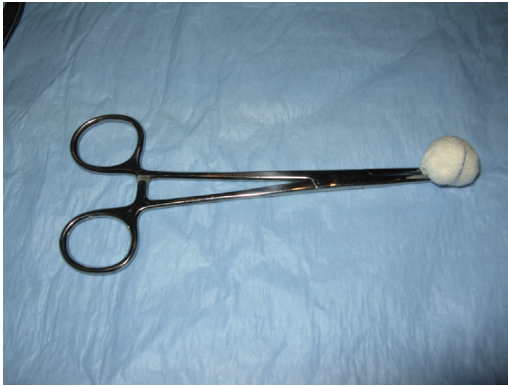Next, an airway guide is inserted (if fiber optic intubation is planned; **Fig. 8**). Then more 4% lidocaine is administered through the airway guide using the MADgic Laryngo-Tracheal Mucosal Atomization Device (**Figs. 9–11**).

This step is then followed by an immediate preintubation review: confirming that the tracheal tube is taped to the fiber optic scope to prevent slippage, checking that the scope suction is working, checking for good image quality and for correct white balancing, and checking that the propofol is attached to the IV line to ensure ease of starting general anesthesia when the tracheal tube is known to be correctly positioned.

Next, the fiber optic scope is introduced via the airway guide and the epiglottis and the vocal cords are identified. A jaw thrust is sometimes helpful to optimize the alignment of the airway structures. Also, at this point, some clinicians like to administer additional lidocaine via an epidural catheter placed in the biopsy channel of the scope.



**Fig. 5.** One popular method of carrying out topical airway anesthesia to oropharyngeal and periglottic structures is to apply 3 to 4 cm of 5% lidocaine paste on the end of a wooden tongue blade, instructing the patient to place the gooeey end as far posteriorly in the mouth as possible. Patients should then gently bite on the blade and avoid sucking, letting the paste liquefy onto the airway structures for about 10 minutes.



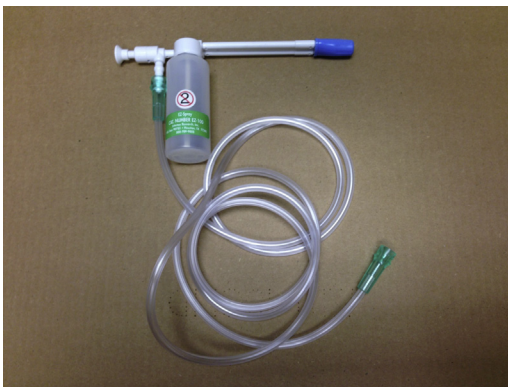**Fig. 6.** Apply 4% lidocaine-soaked gauze on a clamp and apply to the pyriform fossa to block the glossopharyngeal nerve and thus the gag reflex (the sensory portion of the glossopharyngeal nerve innervates the posterior third of the tongue, the palatine tonsils, and the mucous membranes of the oropharynx).

Next, the bronchoscope is passed by the cords into the trachea, the carina is identified, the tracheal tube is passed, the tracheal tube cuff is inflated, the patient breathing circuit is connected, and correct tracheal tube positioning should be checked clinically and by capnography.

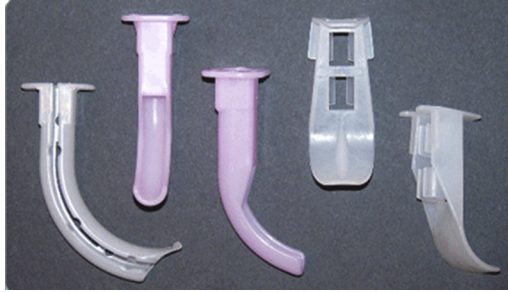
Finally, anesthesia is induced; both IV and inhalational methods can be used.

## NASAL INTUBATION

In cases in which nasal intubation is required, the following additional steps apply after completion of airway topicalization. Patients are instructed to compare their nasal airflow while alternately breathing through the right and left nostril. The nostril with the best airflow is the initial choice for nasotracheal intubation. A spray of 4% cocaine is administered to both nostrils using wide cotton pledgets placed with the aid of alligator forceps. Alternately, a combination of 1% phenylephrine and 4% lidocaine may be used in a 50/50 mixture.



**Fig. 7.** An oxygen-driven power sprayer can be used to deliver lidocaine to oropharyngeal and glottic structures. Oxygen at 15 liters per minute is used as the gas source. Known as the *EZ-Spray*, this unit is available from Intertex Research, Houston, TX. (*EZ-Spray*, Intertex Research).



**Fig. 8.** Airway guides can be useful to facilitate passage of the bronchoscope and tracheal tube. From left to right: Berman, Williams, and Ovassapian airways. (Courtesy of Airway Cam, Wayne, PA; with permission).

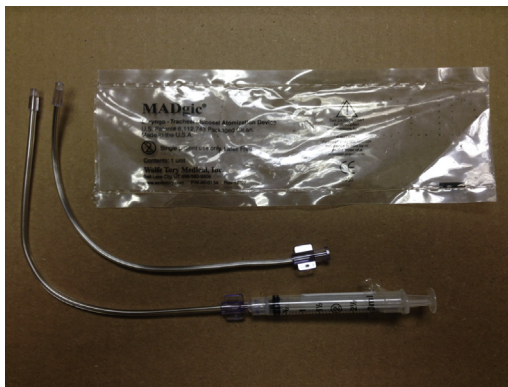
Although awake nasal intubation is generally completed using fiber optic methods, it can also be achieved via direct or video laryngoscopy.

### ***Fiber Optic Technique***

After preparation of the nostrils with one of the above preparations, a well-lubricated endotracheal tube (typically 6.5–7.5 mm inside diameter) is secured to a fiber optic bronchoscope. When the scope has been advanced well into the trachea, the endotracheal tube is railroaded over the scope into position. Twisting may be needed to bypass soft tissue obstruction. The cuff is then inflated, the tube connected to the patient breathing circuit, and correct positioning established by a combination of clinical, capnographic, and fiber optic means.

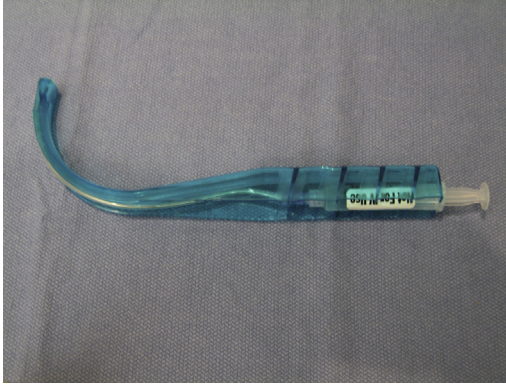### ***Technique Using Laryngoscopy***

After preparation of the nostrils as discussed earlier, and after testing that the airway is sufficiently well topicalized to allow for awake laryngoscopy, a well-lubricated endotracheal tube previously softened by immersion in hot water is inserted along the floor of the nasal cavity. The tube is directed straight back toward the occiput (not cephalad). Twisting may be needed to bypass soft tissue obstruction. At 6 to 7 cm, one



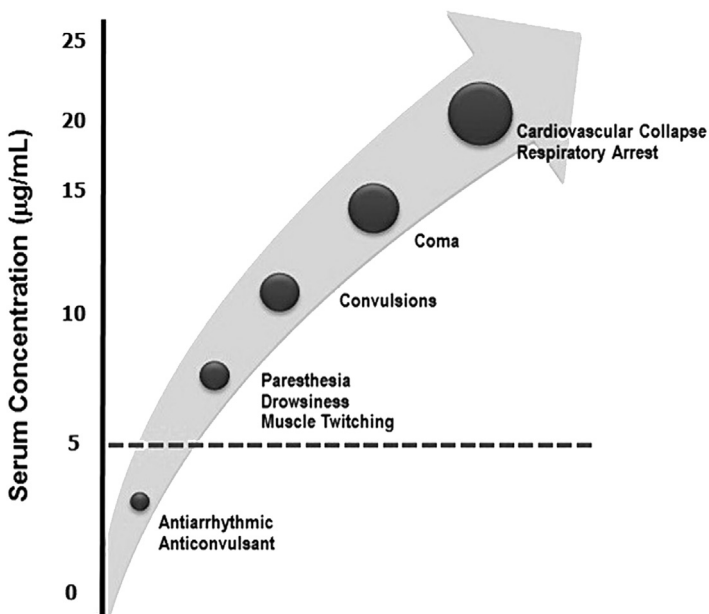
**Fig. 9.** The malleable LMA MADgic Laryngo-Tracheal Mucosal Atomization Device can be useful to assist in the delivery of topical anesthesia to the periglottic structures (For more information see [http://www.teleflex.com/emea/documentLibrary/documents/940716-000001\\_LMA-TF-MADgic\\_1305.pdf](http://www.teleflex.com/emea/documentLibrary/documents/940716-000001_LMA-TF-MADgic_1305.pdf)). (Teleflex, Wayne, PA).





**Fig. 10.** The malleable LMA MADgic Laryngo-Tracheal Mucosal Atomization Device is also available for use with a disposable rigid guide. (Teleflex, Wayne, PA).

often feels a “give” as the tube passes the nasal choana and enters the nasopharynx. Awake laryngoscopy is then used to visualize the vocal cords and the tip of the endotracheal tube. Using Magill forceps held in the right hand, the endotracheal tube is advanced into the larynx when direct laryngoscopy is used. When video laryngoscopy is used, Boedeker (curved) intubation forceps should be used instead of Magill forceps, although simple manipulation of the head to match the glottic aperture to the



**Fig. 11.** The types of complications that can occur when local anesthetics are administered in toxic concentrations. In the case of lidocaine, toxicity may occur at blood concentrations exceeding 5 µg/mL. (From Becker DE, Reed KL. Local anesthetics: review of pharmacological considerations. *Anesth Prog* 2012;59(2):90–101; with permission).

trajectory of the tube is sometimes all that is needed. Note that awake nasal intubation using laryngoscopy typically involves more unpleasantness to the patient compared with awake nasal intubation using fiber optic means.

### LOCAL ANESTHETIC SAFETY

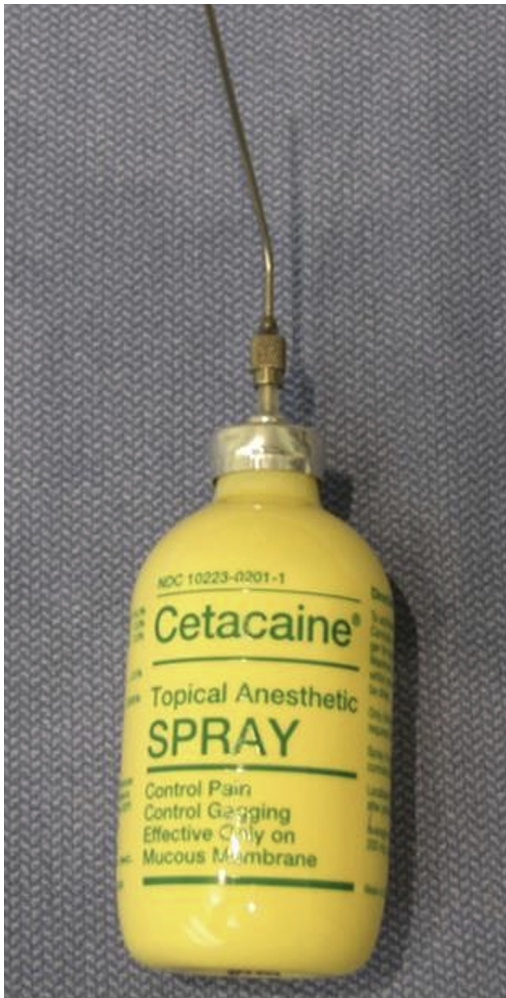Although local anesthetics have an impressive history of efficacy and safety in clinical medicine, they are not free of potential adverse effects, especially when given in large doses.<sup>24–31</sup> For plain lidocaine (no added epinephrine), the recommended maximum administered dose is 5 mg/kg or 400 mg for a typical 80-kg man. However, given that this recommendation is intended for cases in which the lidocaine is administered by infiltration (eg, for a plexus block) it would seem that larger doses would be safe in cases in which the drug is mostly gargled and then expectorated. To draw on an analogy, lidocaine doses as large as 35 mg/kg are sometimes given when tumescent anesthesia is used in liposuction procedures.<sup>32</sup> Then again, tumescent anesthesia has been associated with occasional fatal lidocaine toxicity.<sup>33</sup> The types of complications that can occur when local anesthetics are administered in toxic amounts are illustrated in **Fig. 8**.

Guidelines for the management of local anesthetic toxicity have been published by several groups: the American Society of Regional Anesthesia and Pain Medicine (ASRA),<sup>34</sup> the Association of Anaesthetists of Great Britain and Ireland (AAGBI, 2007),<sup>35</sup> and the Resuscitation Council of the United Kingdom. The core principles of management of local anesthetic toxicity involve the termination of seizures, cardiopulmonary support, and use of the lipid rescue protocol where applicable.<sup>36,37</sup> (Because benzodiazepines have limited potential for causing myocardial depression, ASRA recommends these drugs as first-line treatment of local anesthetic-induced seizures).<sup>34</sup> **Fig. 9** from the AAGBI provides additional details.

### BENZOCAINE

Although benzocaine is an effective topical anesthetic and is the main component of the popular local anesthetic, Citacaine (**Fig. 12**), it has fallen out of favor in recent years. This is because benzocaine administration is sometimes complicated by methemoglobinemia, the presence of elevated methemoglobin levels within circulating erythrocytes. Methemoglobin, being darkly pigmented, causes blood to appear chocolate colored and the patient to look cyanotic. Dark arterial blood and cyanosis out of proportion to the amount of respiratory distress is suggestive of methemoglobinemia, which, incidentally, can be caused by numerous things other than benzocaine administration (eg, antimalarials such as chloroquine or primaquine, as well as nitrites, nitrates, inhaled nitric oxide, and nitroprusside).

As an example, Sachdeva and colleagues<sup>38</sup> describe a case of a man who underwent transesophageal echocardiography for evaluation of endocarditis in which topical 20% benzocaine spray was administered for oropharyngeal anesthesia. Before the topicalization, the patient's oxygen saturation by pulse oximetry was 97% on room air, but after the benzocaine spray it decreased to 80% despite oxygen administration. Clinically, the patient was cyanotic. Methemoglobinemia was suspected, and arterial blood gas evaluation by CO-oximetry (with the patient on 6 L oxygen via nasal cannula) found the following: pH, 7.42;  $P_{O_2}$ , 248;  $P_{CO_2}$ , 34; oxygen saturation, 99%; and methemoglobin, 41.8% of total hemoglobin. After treatment with intravenous methylene blue, 2 mg/kg, the cyanosis resolved and a repeat methemoglobin level 2 hours later was 2.8% (Methylene blue acts as a reducing agent via the NADPH methemoglobin reductase pathway.)



**Fig. 12.** Cetacaine is a topical anesthetic spray containing benzocaine 14.0%, butamben 2.0%, and tetracaine hydrochloride 2.0%.

Abdel-Aziz and colleagues<sup>39</sup> similarly described the methemoglobinemia with the use of benzocaine spray for awake fiber optic intubation. Another example, Ferraro-Borgida and colleagues<sup>40</sup> described methemoglobinemia in a 34-year-old woman after the perineal application of an over-the-counter cream containing 20% benzocaine.

Finally, clinicians and parents will be interested to know that benzocaine is the active ingredient in many over-the-counter teething pain gels and liquid medications, like Anbesol and Baby Orajel; for the above reasons, the US Food and Drug Administration advises against the use of such products in children younger than 2 years.<sup>41</sup>

#### **FUTURE CONSIDERATIONS/SUMMARY**

The safe and effective application of local anesthesia for awake intubation requires attention to several technical details. Patient sedation is less important than ensuring

good airway anesthesia. Although lidocaine is preferred over benzocaine, lidocaine toxicity may occur at blood concentrations exceeding 5 µg/mL. Although many clinicians avoid administering more than 5 mg/kg of topical lidocaine (the frequently recommended maximum dose for infiltration), this limit may be conservative in a setting in which much of the drug is not absorbed. Research is needed to clarify this matter; a reasonable starting point would be to systematically measure blood lidocaine levels for various airway topicalization protocols.<sup>31,42-44</sup>

## REFERENCES

1. Berkow LC. Strategies for airway management. *Best Pract Res Clin Anaesthesiol* 2004;18(4):531-48.
2. Apfelbaum JL, Hagberg CA, Caplan RA, et al, American Society of Anesthesiologists Task Force on Management of the Difficult Airway. Practice guidelines for management of the difficult airway: an updated report by the American Society of Anesthesiologists Task Force on Management of the Difficult Airway. *Anesthesiology* 2013;118(2):251-70.
3. Niven AS, Doerschug KC. Techniques for the difficult airway. *Curr Opin Crit Care* 2013;19(1):9-15.
4. Law JA, Broemling N, Cooper RM, et al, Canadian Airway Focus Group. The difficult airway with recommendations for management—part 1—difficult tracheal intubation encountered in an unconscious/induced patient. *Can J Anaesth* 2013;60(11):1089-118.
5. Law JA, Broemling N, Cooper RM, et al, Canadian Airway Focus Group. The difficult airway with recommendations for management—part 2—the anticipated difficult airway. *Can J Anaesth* 2013;60(11):1119-38.
6. Wanderer JP, Ehrenfeld JM, Sandberg WS, et al. The changing scope of difficult airway management. *Can J Anaesth* 2013;60(10):1022-4.
7. Wong DT, Mehta A, Tam AD, et al. A survey of Canadian anesthesiologists' preferences in difficult intubation and "cannot intubate, cannot ventilate" situations. *Can J Anaesth* 2014;61(8):717-26.
8. Difficult Airway Society Extubation Guidelines Group, Popat M, Mitchell V, et al. Difficult Airway Society Guidelines for the management of tracheal extubation. *Anaesthesia* 2012;67(3):318-40.
9. Yeh L, Chen HS, Tan PH, et al. Difficult fiber-optic intubation in a patient with giant neck masses: the role of McCoy laryngoscope in elevating compressed laryngeal aperture. *Acta Anaesthesiol Taiwan* 2013;51(4):180-3.
10. Wood A, Choromanski D, Orlewicz M. Intubation of patients with angioedema: A retrospective study of different methods over three year period. *Int J Crit Illn Inj Sci* 2013;3(2):108-12.
11. Srivastava D, Dhiraaj S. Airway management of a difficult airway due to prolonged enlarged goiter using loco-sedative technique. *Saudi J Anaesth* 2013;7(1):86-9.
12. Kothandan H, Ho VK, Chan YM, et al. Difficult intubation in a patient with vallecular cyst. *Singapore Med J* 2013;54(3):e62-5.
13. Langeron O, Birenbaum A, Le Saché F, et al. Airway management in obese patient. *Minerva Anesthesiol* 2014;80(3):382-92.
14. Horton CL, Brown CA 3rd, Raja AS. Trauma airway management. *J Emerg Med* 2014;46(6):814-20.
15. Ghabach MB, Abou Rouphael MA, Roumoulian CE, et al. Airway management in a patient with Le Fort III Fracture. *Saudi J Anaesth* 2014;8(1):128-30.

16. Butterworth JF 4th, Strichartz GR. Molecular mechanisms of local anesthesia: a review. *Anesthesiology* 1990;72(4):711–34.
17. Scheuer T. Local anaesthetic block of sodium channels: raising the barrier. *J Physiol* 2007;581(Pt 2):423.
18. Rothfield KP, Russo SG. Videolaryngoscopy: should it replace direct laryngoscopy? a pro-con debate. *J Clin Anesth* 2012;24(7):593–7.
19. Curtis R. Awake videolaryngoscopy-assisted tracheal intubation in the morbidly obese. *Anaesthesia* 2012;67(7):796–7 [author reply: 799].
20. Healy DW, Maties O, Hovord D, et al. A systematic review of the role of videolaryngoscopy in successful orotracheal intubation. *BMC Anesthesiol* 2012;12:32.
21. Larsson A, Dhonneur G. Videolaryngoscopy: towards a new standard method for tracheal intubation in the ICU? *Intensive Care Med* 2013;39(12):2220–2.
22. Gu J, Xu K, Ning J, et al. GlideScope-assisted fiberoptic bronchoscope intubation in a patient with severe rheumatoid arthritis. *Acta Anaesthesiol Taiwan* 2014;52(2):85–7.
23. Agro' FE, Doyle DJ, Vennari M. Use of Glidescope in adults: an overview. *Minerva Anesthesiol* 2015;81(3):342–51.
24. Clapp CR, Poss WB, Cilento BG. Lidocaine toxicity secondary to postoperative bladder instillation in a pediatric patient. *Urology* 1999;53(6):1228.
25. Moore PA, Hersh EV. Local anesthesia toxicity review revisited. *Pediatr Dent* 2000;22(1):7–8.
26. Zuberi BF, Shaikh MR, Jatoi NU, et al. Lidocaine toxicity in a student undergoing upper gastrointestinal endoscopy. *Gut* 2000;46(3):435.
27. Chang YY, Ho CM, Tsai SK. Cardiac arrest after intraurethral administration of lidocaine. *J Formos Med Assoc* 2005;104(8):605–6.
28. Nishiyama T, Komatsu K. Local anesthetic toxicity in interscalene block: clinical series. *Minerva Anesthesiol* 2010;76(12):1088–90.
29. Menif K, Khaldi A, Bouziri A, et al. Lidocaine toxicity secondary to local anesthesia administered in the community for elective circumcision. *Fetal Pediatr Pathol* 2011;30(6):359–62.
30. Wolfe JW, Butterworth JF. Local anesthetic systemic toxicity: update on mechanisms and treatment. *Curr Opin Anaesthesiol* 2011;24(5):561–6.
31. Giordano D, Panini A, Pernice C, et al. Neurologic toxicity of lidocaine during awake intubation in a patient with tongue base abscess. Case report. *Am J Otolaryngol* 2014;35(1):62–5.
32. Klein JA. Tumescence technique for regional anesthesia permits lidocaine doses of 35 mg/kg for liposuction. *J Dermatol Surg Oncol* 1990;16(3):248–63.
33. Rao RB, Ely SF, Hoffman RS. Deaths related to liposuction. *N Engl J Med* 1999; 13:1471–5.
34. Neal JM, Bernardis CM, Butterworth JF 4th, et al. ASRA practice advisory on local anesthetic systemic toxicity. *Reg Anesth Pain Med* 2010;35(2):152–61.
35. Picard J, Ward SC, Zumpe R, et al. Guidelines and the adoption of 'lipid rescue' therapy for local anaesthetic toxicity. *Anaesthesia* 2009;64(2):122–5.
36. Litz RJ, Roessel T, Heller AR, et al. Reversal of central nervous system and cardiac toxicity after local anesthetic intoxication by lipid emulsion injection. *Anesth Analg* 2008;106(5):1575–7.
37. Leskiw U, Weinberg GL. Lipid resuscitation for local anesthetic toxicity: is it really lifesaving? *Curr Opin Anaesthesiol* 2009;22(5):667–71.
38. Sachdeva R, Pugada JG, Casale LR, et al. Benzocaine-induced methemoglobinemia: a potentially fatal complication of transesophageal echocardiography. *Tex Heart Inst J* 2003;30(4):308–10.

39. Abdel-Aziz S, Hashmi N, Khan S, et al. Methemoglobinemia with the use of benzocaine spray for awake fiberoptic intubation. *Middle East J Anesthesiol* 2013;22(3):337–40.
40. Ferraro-Borgida MJ, Mulhern SA, DeMeo MO, et al. Methemoglobinemia from perineal application of an anesthetic cream. *Ann Emerg Med* 1996;27: 785–8.
41. So TY, Farrington E. Topical benzocaine-induced methemoglobinemia in the pediatric population. *J Pediatr Health Care* 2008;22(6):335–9 [quiz: 340–1].
42. Guler P, El Saleeby C, Watt LD, et al. Elevated lidocaine serum levels following the use of a needle free device in healthy adult volunteers. *Pediatr Emerg Care* 2014; 30(5):335–9.
43. Martin KM, Larsen PD, Segal R, et al. Effective nonanatomical endoscopy training produces clinical airway endoscopy proficiency. *Anesth Analg* 2004;99(3): 938–44.
44. Woodall NM, Harwood RJ, Barker GL. Lidocaine toxicity in volunteer subjects undergoing awake fiberoptic intubation. *Anesth Analg* 2005;101(2):607 [author reply: 607].
45. Cattano D, Lam NC, Ferrario L, et al. Dexmedetomidine versus Remifentanil for Sedation during Awake Fiberoptic Intubation. *Anesthesiology Research and Practice* 2012;2012:7. Available at: <http://www.hindawi.com/journals/arp/2012/753107/>.